RJO 2021

RAJASTHAN JOURNAL OF OPHTHALMOLOGY

FROM DARKNESS TO LIGHT

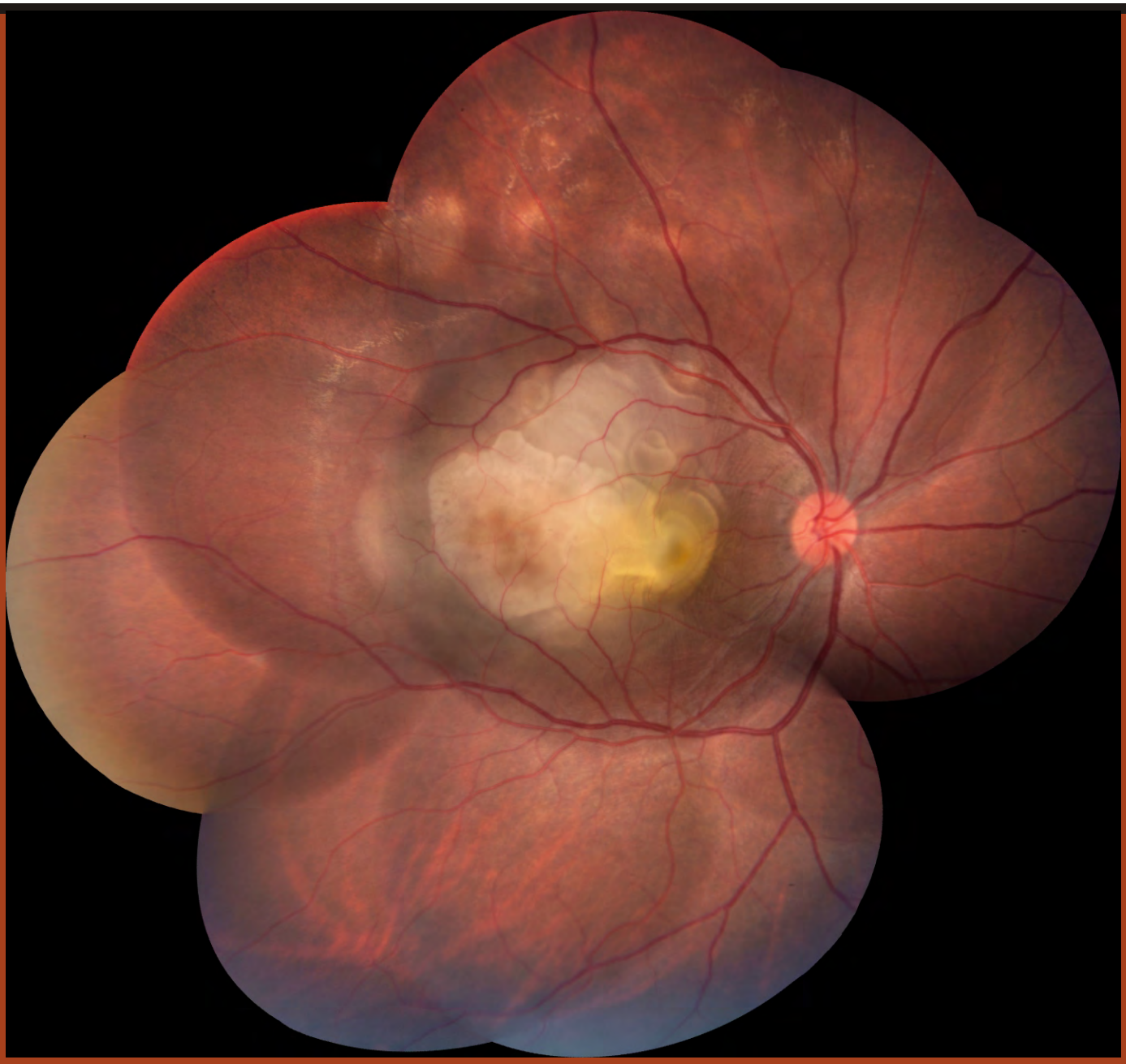

Official Scientific Journal of

Rajasthan Ophthalmological Society

Editorial Address :

Dr. Suresh K. Pandey
SuVi Eye Institute & Lasik Laser Centre
C-13 Talwandi, Kota , Rajasthan
Phone 93514-12449
Email: suresh.pandey@gmail.com

ROS EXECUTIVE COMMITTEE

DR. R. K. SHARMA
President

DR. SANDEEP VIJAY
Hon. General Secretary

DR. K. K. KANJOLIA
President Elect

DR. KAMLESH KHILNANI
Vice President

DR. PRATUL TYAGI
Treasurer

DR. HARSHUL TAK
Chairman, Scientific Committee

DR. SURESH K. PANDEY
Editor Journal

DR. ANIL GOYAL
Executive Member

DR. ANKUR SINHA
Executive Member

DR. RAJESH GOEL
Executive Member

DR. TANMAY KABRA
Executive Member

DR. RAKESH PORWAL
Executive Member, Ajmer Zone

DR. MITHILESH KHANDELWAL
Executive Member, Bharatpur Zone

DR. SOURABH BHARGAVA
Executive Member, Bikaner Zone

DR. R. K. VERMA
Executive Member, Jaipur Zone

DR. ARVIND CHOUHAN
Executive Member, Jodhpur Zone

DR. RAJENDRA CHANDEL
Executive Member, Kota Zone

DR. A. K. BAIRWA
Executive Member, Udaipur Zone

DR. PAWAN SHOREY
Advisor

DR. ANIL KOTHARI
Advisor

DR. MADHU MATHUR
Immediate Past President

DR. MUKESH SHARMA
Immediate Past Hon. General Secretary

CONTENTS

CONTENTS

EDITOR'S DESK

Dr. Suresh K. Pandey

Editor Journal & Proceedings

Dear ROS Members,

I would like to express my heartfelt thanks to all of you for giving me the opportunity to serve as an Editor Journal of our prestigious Rajasthan Ophthalmological Society (ROS). This journal is brought to you after a small hiatus as all of us faced the challenges posed by the COVID-19 pandemic.

It gives me immense pleasure to present *RJO 2021*. This issue contains several articles useful in our day-to-day ophthalmology practice. A galaxy of renowned ophthalmologists have shared case reports, research studies, articles on retinoblastoma, phaco in small pupil, SMILE refractive surgery, management of infective keratitis and therapeutic modalities for ARMD. In addition to clinical ophthalmology articles, tips to restore dignity of medical (ophthalmic) profession and secrets of successful ophthalmic practice are also shared.

I sincerely thank all the esteemed authors for submitting their valuable articles for publication in RJO and also all other authors whose articles could not be included in this issue. I would like to encourage them to send these for the next issue.

My sincere thanks to editorial board members for their support and encouragement. The PDF version of this issue will also be made available to all members in their inbox and also on the website of ROS.

I look forward to receiving your valuable feedback and suggestions.

Wishing you a great scientific feast.

Suresh K Pandey

Dr. Suresh K. Pandey
Editor Journal and Proceedings,
Rajasthan Ophthalmological Society (ROS)
E-mail:suresh.pandey@gmail.com

Recent Advances in Retinoblastoma during COVID-19 Times

Dr. Rolika Bansal, MS, Dr. Santosh G Honavar, MD, FACS, FRCOphth
Centre for Sight, Hyderabad, India
E-mail: santosh.honavar@gmail.com

INTRODUCTION

Considering the advent of the coronavirus SARS-CoV-2 and the associated COVID-19 pandemic, the world has seen a stand-still like never before. As the World Health Organization (WHO) declared COVID-19, a Public Health Emergency of International Concern (PHEIC)[1], a world-wide lockdown was announced and the medical practice and patterns were adversely affected due to the inability of patients to reach their primary treating centre. The pandemic affected the management patterns of several diseases in the world of oncology[2] including pediatric cancers like retinoblastoma. Several protocols were introduced for the management of children with retinoblastoma affected due to the delay in treatment.[3,4]

Based on the in-depth examination under anesthesia at the time of presentation after loss-to-follow up (LFU), in retinoblastoma patients, the clinicians are required to tailor the management to ensure life, globe and vision salvage to the best of their capacity.[3,5]As a consequence, the need for a clear understanding of the importance of the recent advances of retinoblastoma management, is advocated.

Here, we are enlisting the recent advances in retinoblastoma treatment modalities.

SUPER-SELECTIVE OPHTHALMIC INTRA-ARTERIAL CHEMOTHERAPY (IAC)

Intra-arterial chemotherapy is a promising procedure requiring a well-crafted team of ocular oncologists, pediatric oncologists, radiation interventionists, and occasionally neuro-radiologists and neurosurgeons. Yamane *et al*, first introduced the technique of IAC for the management of retinoblastoma[6]. After its introduction in 1998, the procedure has evolved through different phases and has shown to be more effective than the conventional systemic intravenous chemotherapy (IVC). Over the years, there have been tremendous developments.

From selective ophthalmic artery infusion (SOAI)[6] to super-selective ophthalmic artery IAC[7]and single drug protocols (with melphalan only)[8] to triple drug regimens (adding carboplatin and topotecan).[9]In patients after LFU due to the COVID-19 pandemic, the technique of IAC has shown excellent outcomes when used as secondary, tandem, bridge or rescue IAC.

Secondary IAC

Children either regressed or undergoing treatment prior to LFU have shown excellent outcome with super-selective ophthalmic intra-arterial chemotherapy. The treatment is also considered secondary when followed by failure of previous treatment.

Tandem IAC

With the possibility of active tumor in both eyes, tandem IAC holds a good place in the management with bilateral simultaneous delivery of IAC.

Bridge IAC

Considering the presentation, some children might require post-IVC initiation of IAC.

Rescue IAC

Children who have undergone IAC earlier, undergo re-initiation of IAC post COVID-19 pandemic for the tumor recurrence or subretinal seeds.

Acceptable standardized protocols of universal consensus are yet to be published, however, a 4 weekly regimen of 3 sessions has been recommended considering the previous studies.[7,10–12] With minimal systemic complications and maximum efficacy, IAC is a preferred modality based on the systemic status of the children[13,14] with a globe retention ranging from 30% to 100% and success rate of 91% to 100%.[15]

INTRAVITREAL CHEMOTHERAPY (IVITC)

Due to LFU, focal or diffuse vitreous seeding i.e. spread of viable tumor cells within the vitreous cavity (Figure 1), might occur and it is recommended to understand the importance of intravitreal chemotherapy (IVitC). Previously salvage of vitreous seeds was attempted with external beam radiotherapy, systemic chemotherapy and even enucleation. Intra-arterial

chemotherapy also showed a complete response in 67% cases.[9] However, in 2015, Suzuki *et al* brought in a revolution by introducing their decade long work on assessing safety and efficacy of intra-vitreal melphalan for vitreous seeds showing complete remission in 68% cases with retained vision in half of the cases and low risk of extra ocular tumor spread.[16]Topotecan is less toxic, more effective and can be spaced out to 3-weekly injections.[17] In case of presence of tumor or vitreous seeds at the site of planned needle entry, pars plana invasion of tumor and anterior chamber seeding; IVitC is contra-indicated.[18]

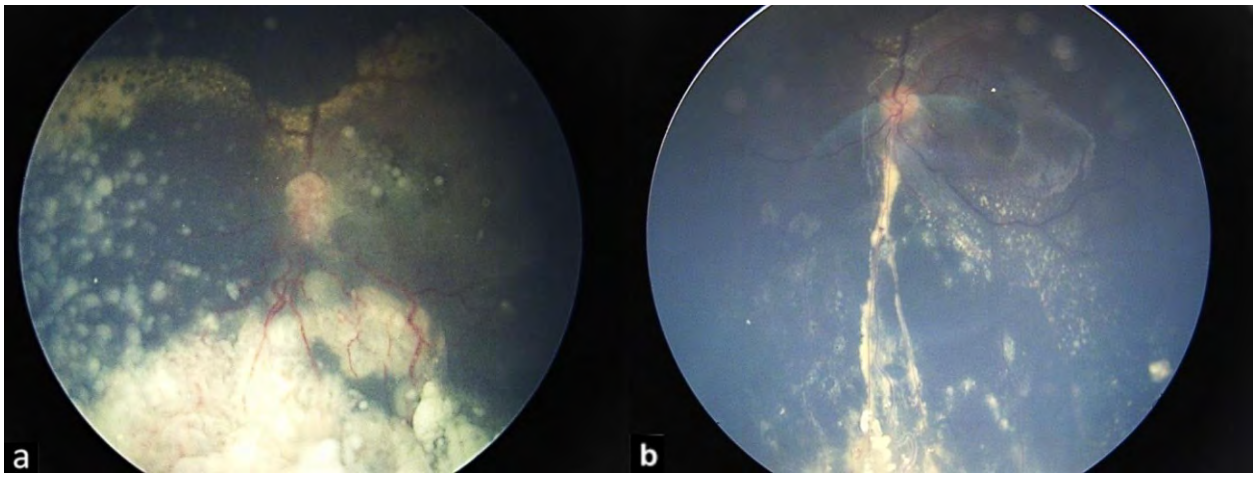

Figure 1: Intra-vitreal topotecan: (a) Diffuse clouds, spheres and dusts of vitreous seeds with active retinal seeding (b) Four cycles of IVT administered at 4-weekly regimen with complete regression of vitreous seeds.

PRECISION INTRAVITREAL CHEMOTHERAPY (P-IVITC)

Precision intravitreal chemotherapy (p-IVitC) introduced in 2018, is designed to treat single or localized group of vitreous seeds under indirect ophthalmoscopy, using gravitational force for obtaining higher efficacy. This technique reduced mean injection from 4-5 to 2.6 with a prolonged tumor control at 10 months follow-up. [19,20]

INTRACAMERAL CHEMOTHERAPY (ICAMC)

Due to the significant gap between treatment interventions, if the children develop focal or diffuse anterior chamber seeds, it is recommended to give intracameral chemotherapy instead of the older practices of immediate enucleation or anterior chamber plaque radiotherapy. In 2017

Munier *et al*, introduced the technique of IcamCto provide tumoricidal doses localized to the anterior chamber[21]. Melphalan (15-20 µg/0.05mL) or topotecan (7.5 µg/0.015mL) are the preferred dosages.

ICG ENHANCED TRANSPUPILLARY THERMOTHERAPY (TTT)

Transpupillary thermotherapy (TTT) is performed using a810 nm diode laser on continuous mode. However, at times it is required to enhance the effect of TTT with 0.3-0.5 mg/kg infusion of ICG one minute prior to administration of TTT. This is preferred in tumors with sub-optimal response to TTT on previous visits (Figure 2).

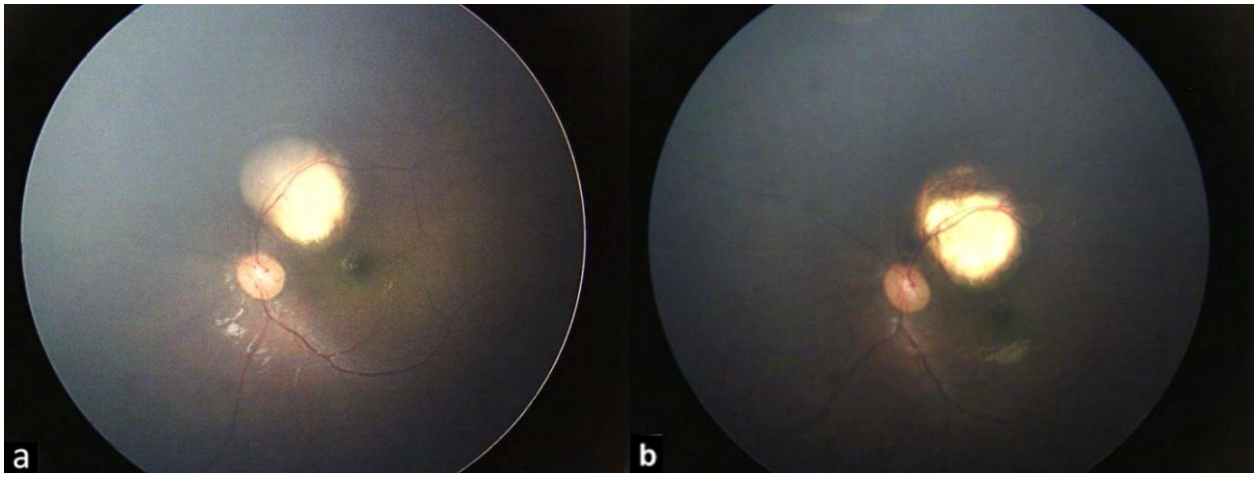

Figure 2: ICG enhanced TTT: (a) Active tumor along the superior-arcade with sub-optimal response to TTT (b) Six sessions of ICG-enhanced TTT led to complete regression with flat scar.

PLAQUE BRACHYTHERAPY

Another recent advancement that comes handy in treatment of tumors showing suboptimal response to other treatment modalities, especially after a significant LFU, is plaque brachytherapy (Figure 3). Plaque brachytherapy can be used as secondary treatment for chemo-resistant tumors (<16mm in largest basal diameter and > 3 to <9 mm in thickness).

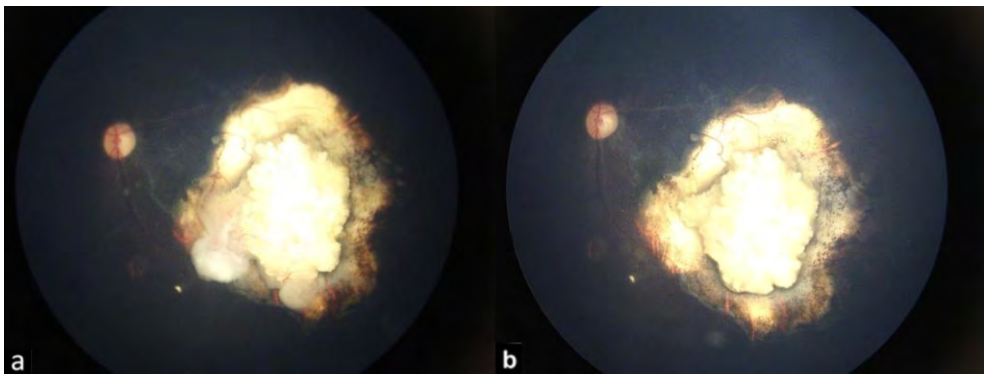

Figure 3: Plaque Brachytherapy: (a) An active chemo-resistant partly calcified tumor (b) Excellent response to plaque brachytherapy with complete regression.

MULTI-MODAL MANAGEMENT OF ORBITAL RETINOBLASTOMA

In active cases before LFU, there are high chances of development of orbital retinoblastoma due to the hiatus created in the treatment by the pandemic (Figure 4). Factors like invasion of orbit and optic nerve are considered as factors for early prediction of metastatic retinoblastoma[22]. However, due to LFU it might be difficult to recognize these factors and the child might present at a stage of grave prognosis. In such cases, considering the high mortality rate, it is advocated to proceed with a multimodal management wherein sequentially treatment is given i.e. neoadjuvant high-dose chemotherapy, extended enucleation, stereotactic radiotherapy and additional adjuvant chemotherapy to improve the outcome. [23,24]

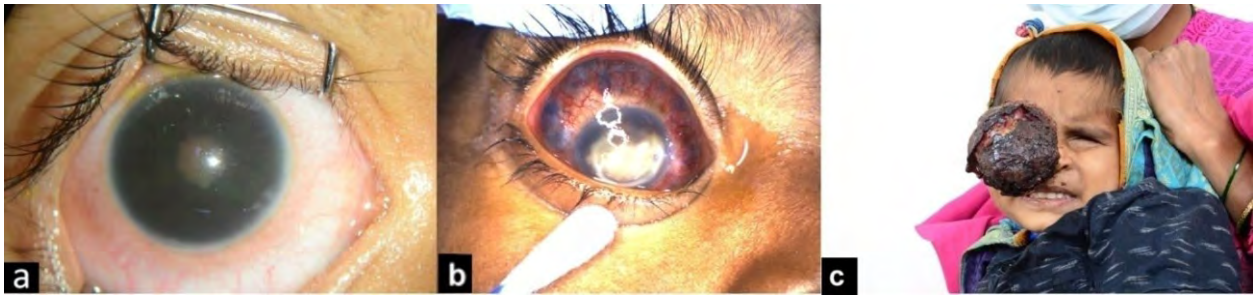

Figure 4: Orbital retinoblastoma: (a) Focal anterior chamber seeds with diffuse neovascularization of iris and 360 degrees posterior synechiae and was advised to undergo immediate enucleation. However, he was lost to follow-up due to the COVID-19 pandemic. (b) After a LFU of 10 months the child came proptosis and an anterior staphyloma (c) After a further LFU of 3 months the child developed Orbital retinoblastoma presenting as a fungating mass from the right eye. *(Courtesy - With permission from Indian Journal of Ophthalmology[5]).*

CONCLUSION

The recent advances in retinoblastoma have played a significant role in altering the morbidity and mortality spike created by the COVID-19 pandemic. A combination and sequential approach adopted by the ocular oncologist based on the presentation (as per the clinical examination under anesthesia, radiological and systemic assessment) after LFU results in excellent tumor control and optimal vision, eye and life salvage.

REFERENCES

1. COVID-19 Public Health Emergency of International Concern (PHEIC) Global research and innovation forum [Internet]. [cited 2021 Dec 13]. Available from: https://www.who.int/publications/m/item/covid-19-public-health-emergency-of-international-concern-(pheic)-global-research-and-innovation-forum

2. The Lancet Oncology. COVID-19: global consequences for oncology. Lancet Oncol. 2020 Apr;21(4):467.

3. Manjandavida FP, Honavar SG, Kim U, Singh U, Menon V, Das S, et al. Ocular oncology practice guidelines during COVID-19 pandemic-An expert consensus. Indian J Ophthalmol. 2020 Jul;68(7):1281–91.

4. Bouffet E, Challinor J, Sullivan M, Biondi A, Rodriguez-Galindo C, Pritchard-Jones K. Early advice on managing children with cancer during the COVID-19 pandemic and a call for sharing experiences. Pediatr Blood Cancer. 2020 Jul;67(7):e28327.

5. Bansal R, Aishwarya A, Rao R, Christy MC, Sen M, Regani H, et al. Impact of COVID-19 nationwide lockdown on retinoblastoma treatment and outcome: A study of 476 eyes of 326 children. Indian J Ophthalmol. 2021 Oct;69(10):2617–24.

6. Yamane T, Kaneko A, Mohri M. The technique of ophthalmic arterial infusion therapy for patients with intraocular retinoblastoma. Int J Clin Oncol. 2004 Apr;9(2):69–73.

7. Gobin YP, Dunkel IJ, Marr BP, Brodie SE, Abramson DH. Intra-arterial chemotherapy for the management of retinoblastoma: four-year experience. Arch Ophthalmol Chic Ill 1960. 2011 Jun;129(6):732–7.

8. Inomata M, Kaneko A. Chemosensitivity profiles of primary and cultured human retinoblastoma cells in a human tumorclonogenic assay. Jpn J Cancer Res Gann. 1987 Aug;78(8):858–68.

9. Abramson DH, Dunkel IJ, Brodie SE, Kim JW, Gobin YP. A phase I/II study of direct intraarterial (ophthalmic artery) chemotherapy with melphalan for intraocular retinoblastoma initial results. Ophthalmology. 2008 Aug;115(8):1398–404, 1404.e1.

10. Suzuki S, Yamane T, Mohri M, Kaneko A. Selective ophthalmic arterial injection therapy for intraocular retinoblastoma: the long-term prognosis. Ophthalmology. 2011 Oct;118(10):2081–7.

11. Shields CL, Manjandavida FP, Lally SE, Pieretti G, Arepalli SA, Caywood EH, et al. Intra-arterial chemotherapy for retinoblastoma in 70 eyes: outcomes based on the international classification of retinoblastoma. Ophthalmology. 2014 Jul;121(7):1453–60.

12. Manjandavida FP, Stathopoulos C, Zhang J, Honavar SG, Shields CL. Intra-arterial chemotherapy in retinoblastoma - A paradigm change. Indian J Ophthalmol. 2019;67(6):740–54.

13. Yousef YA, Soliman SE, Astudillo PPP, Durairaj P, Dimaras H, Chan HSL, et al. Intra-arterial Chemotherapy for Retinoblastoma: A Systematic Review. JAMA Ophthalmol. 2016 May 1;134(5):584–91.

14. Chantada G, Schaiquevich P. Intra-arterial Chemotherapy for Retinoblastoma. JAMA Ophthalmol. 2016 01;134(10):1202–3.

15. Pekacka A. The Role of Intraarterial Chemotherapy in the Management of Retinoblastoma. J Ophthalmol. 2020;2020:3638410.

16. Suzuki S, Aihara Y, Fujiwara M, Sano S, Kaneko A. Intravitreal injection of melphalan for intraocular retinoblastoma. Jpn J Ophthalmol. 2015 May;59(3):164–72.

17. Rao R, Honavar SG, Sharma V, Reddy VAP. Intravitreal topotecan in the management of refractory and recurrent vitreous seeds in retinoblastoma. Br J Ophthalmol. 2018 Apr;102(4):490–5.

18. Ancona-Lezama D, Dalvin LA, Shields CL. Modern treatment of retinoblastoma: A 2020 review. Indian J Ophthalmol. 2020 Nov;68(11):2356–65.

19. Yu MD, Dalvin LA, Welch RJ, Shields CL. Precision Intravitreal Chemotherapy for Localized Vitreous Seeding of Retinoblastoma. Ocul Oncol Pathol. 2019 Jun;5(4):284–9.

20. Francis JH, Marr BP, Brodie SE, Abramson DH. Anterior Ocular Toxicity of Intravitreous Melphalan for Retinoblastoma. JAMA Ophthalmol. 2015 Dec;133(12):1459–63.

21. Munier FL, Gaillard M-C, Decembrini S, Bongiovanni M, Beck-Popovic M. Intracameral Chemotherapy (Melphalan) for Aqueous Seeding in Retinoblastoma: Bicameral Injection Technique and Related Toxicity in a Pilot Case Study. Ocul Oncol Pathol. 2017 Jul;3(2):149–55.

22. Finger PT, Harbour JW, Karcioglu ZA. Risk factors for metastasis in retinoblastoma. Surv Ophthalmol. 2002 Feb;47(1):1–16.

23. Honavar SG, Singh AD. Management of advanced retinoblastoma. Ophthalmol Clin N Am. 2005 Mar;18(1):65–73, viii.

24. Honavar SG, Manjandavida FP, Reddy VAP. Orbital retinoblastoma: An update. Indian J Ophthalmol. 2017 Jun;65(6):435–42.

SMILE: A New Paradigm in Refractive Surgery

Dr. Sheetal Brar[1], Dr. Sri Ganesh[2]

Nethradhama Superspeciality Eye Hospital, Bengaluru.

[1]Senior consultant & Director of education and research Nethradhama Superspeciality Eye hospital, Bengaluru (E-email: brar_sheetal@yahoo.co.in)

[2]Chairman & Medical Director, Nethradhama Superspeciality Eye Hospital, Bengaluru

INTRODUCTION AND BACKGROUND

Refractive lenticule extraction marks a paradigm shift in the field of refractive surgery from the conventional flap-based corneal ablative procedures to flap-less extraction of femtosecond laser-created intrastromal lenticules. Small incision lenticule extraction (SMILE), a variant of refractive lenticule extraction technology is becoming increasingly popular, as a flapless and minimally invasive form of laser vision correction (LVC) for the treatment of myopia and myopic astigmatism. SMILE received Conformité Européenne (CE) marking in 2009 and was approved by FDA in September 2016 after US pivotal studies.

Refractive surgery through laser vision correction (LVC) has evolved significantly within the past few decades. From the first generation techniques involving surface ablation to Laser *in situ* keratomileusis (LASIK), refractive surgery has now become intrastromal with the advent of refractive lenticule extraction (ReLEx) technology.[1] This procedure when performed through a small incision (2–4 mm) was described as small incision lenticule extraction (SMILE), which is essentially bladeless, flapless and minimally invasive technique compared to LASIK, where a corneal flap is created using either a blade or a femtolaser.[2]

In 1996, investigators first described the use of a picosecond laser to generate an intrastromal lenticule that was removed manually after the flap was lifted. The main drawbacks of this procedure, which was a precursor to modern refractive lenticule extraction was the relatively low precision and accuracy of the laser. The switch to using a femtosecond laser improved the precision of the laser according to the studies performed in rabbit eyes. [3,4]

Following the introduction of the VisuMax femtosecond laser, the intrastromal lenticule method was reintroduced in a procedure called femtosecond lenticule extraction (FLEx). VisuMax

Femtosecond laser has a low-suction curved interface, and no suction ring is applied to the eye. The optical system is designed with very high numerical aperture optics, thus allowing for very tight concentration of femtosecond energy, very little collateral energy dissipation, and high femtosecond spot placement accuracy. The 1043 nm laser fires at 500 kHz with a pulse duration of 220-580 fs. Each femtosecond laser spot creates a photodisruption plane within the cornea. It is possible with the VisuMax laser to create a three dimensional free - form incision plane anywhere within the cornea, with a precise shape. This procedure creates a lenticule in the cornea which can be extracted through a small incision and thus correction of myopic refractive error. The overall efficacy of SMILE is dependent on whether these technical design elements can deliver the precision required for refractive lenticule creation.

PRINCIPLES AND SURGICAL TECHNIQUE

SMILE is usually performed as a day care procedure under topical anesthesia. A curved contact patient interface is used to couple to the femtosecond laser. As the cornea touches the contact glass, a meniscus of tear film appears, and the patient is able to see the fixation target which appears as a green flashing light, clearly because the vergence of the fixation beam is focused according to the patient's refraction.[5]At this point, the patient is instructed to look directly at the green light which essentially infers that the centration in SMILE is patient controlled and is fixed on the visual axis of the eye.[6] Once the centration is confirmed, the suction is activated to fixate the eye in this position. After adequate suction is established, the patient is instructed to hold still, and not to follow the green light if it shifts or to search for it when it disappears.

The centration can also be confirmed by the surgeon using the infrared light, after which the laser is fired. The patient is able to maintain fixation once the suction is activated, and during initial stage of laser delivery due to a much lower intraocular pressure (IOP), as compared to other femtolaser systems.[7] The lower IOP is mainly attributed to the corneal suction and curved contact glass present in theVisuMax femtosecond laser system. IntraLase femtosecond laser has a very strong suction and can cause the patient's vision to black out during the procedure. With the VisuMax, on the other hand, the suction from the curved applanation cone on the cornea is much lesser, which helps to maintain the visibility of the green fixation light throughout the docking process, and leads to lesser incidence of subconjunctival hemorrhages.

The laser first creates the lower interface of the intrastromal lenticule in a spiral in pattern (out-to-in direction), followed by a 360° side cut, followed by creation of the upper interface in a spiral out pattern (in-to-out direction), known as the cap, and finally, a 2–4 mm access incision (usually superior or super temporal) that connects the cap interface to the corneal surface [Figure 1]. Total suction time is approximately 25–35 s (depending on the mode used) and is independent of refractive error treated. For removal of the lenticule, the small incision is opened and the upper and lower interfaces of the lenticule are identified to define the tissue planes.

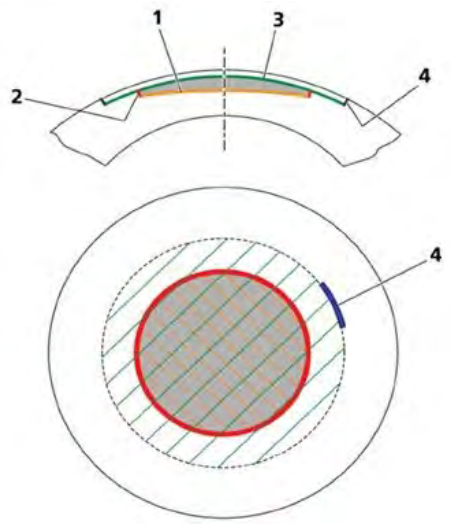

1 Lenticule cut (underside of lenticule)
2 Lenticule side cut
3 Cap cut (concurrently upper side of lenticule)
4 Cap opening incision

Figure 1: The lenticule cut (1) is performed (the underside of the lenticule), followed by the lenticule sidecuts (2). Next, the cap interface (3) is created (the upper side of the lenticule), and finally a 2–3 mm small incision (4) is created superotemporally. The lenticule interfaces are dissected using a flap separator and the lenticule is extracted manually, all via the small incision (Reproduced after permission from Prof Dan Reinstein)

The eye may be stabilized with a fixation forceps to have better control while separating the surgical planes. The upper interface is usually separated first using a blunt end of the dissector, the movement of the instrument being in a windshield wiper like fashion with the fulcrum at the center of the incision. The lower layer of the interface is then dissected in a similar fashion. Once both interfaces are separated, and the lenticule is free, the tissue slides out along with the dissector from the pocket or it is grasped with a pair of micro-forceps and extracted. The lenticule is then examined by placing it on the surface of cornea for its integrity and any loss of tissue [Figure 2].

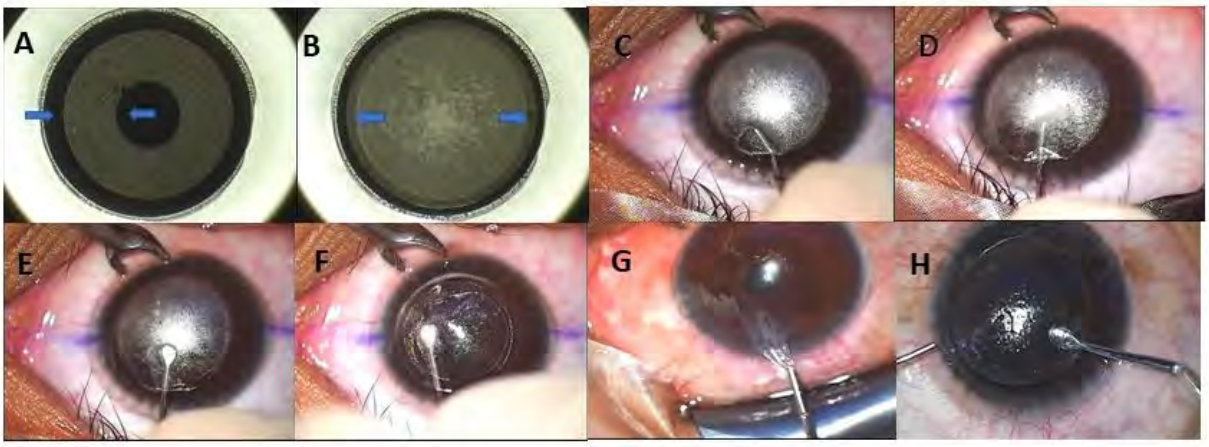

Figure 2- A. spiral in pattern of laser from periphery to center, B. spiral out of laser pattern from center to periphery, C. finding anterior plane of the lenticule, D. finding posterior plane of lenticule, E. dissection of the anterior plane, F. dissection of the posterior plane, G. removal of the lenticule from interface with microforceps, H. examining the lenticule after its removal

At the end of the procedure, some surgeons prefer to flush/wash the interface with saline while others do not perform this step for the concerns of corneal hydration and introduction of infection. In our experience, minimal washing of the interface with balanced salt solution leads

to better visual outcomes on postoperative day 1, possibly due to clearing of the Bowman's membrane folds which occur due to sudden collapse of anterior corneal layers after the lenticule is removed, and surgical manipulations.

PATIENT SELECTION

The SMILE procedure is approved for the treatment of myopia and myopic astigmatism for myopia ranging from -1.00 D to -10.00 D sphere, cylinders from -0.75 D to -5 D and spherical equivalent up to -12.50 D.

Preoperative evaluation is similar to that for patients undergoing photoablative procedures, such as LASIK or photorefractive keratectomy (PRK).

Inclusion criteria: Age 18 years or older with documentation of stable manifest refraction for 1-year, soft contact lens use discontinued for 1 week and rigid gas permeable lens use discontinued for 3 weeks prior to the procedure, minimum corneal thickness of 480 µm, and residual stromal bed of at least 280 µm.

Exclusion Criteria: Evidence of residual or active ocular diseases such as herpetic keratitis, uveitis, glaucoma, visually significant cataract, retinal diseases such as retinal dystrophies or diabetic retinopathy, corneal dystrophies, keratoconus, history of corneal trauma or surgery, severe/ untreated dry eyes , use of systemic medications likely to affect wound healing (e.g., corticosteroids or antimetabolites), immunocompromised state, women who are pregnant or nursing.

ADVANTAGES OF SMILE

There are evidences showing long term safety, efficacy and stability of SMILE in treatment of myopic and myopic astigmatism.[8,9]

From the patient's perspective, this procedure is comfortable as it is painless and recovery is quick.

There is no flap in this procedure therefore no flap related complications like flap striae or flap displacement.

The centration of the cone can be altered during docking with large angle kappa. The green fixation light in SMILE is fixed on the visual axis of the eye which is an advantage in large angle kappa.

SMILE and Dry Eye: The cornea is one of the most densely innervated peripheral tissues in humans. Nerve bundles within the anterior stroma grow radially inward from the periphery towards the central cornea. [10,11] The nerves then penetrate Bowman's layer and create a dense

network of nerve fibers, known as the sub basal nerve plexus by branching both vertically and horizontally between Bowman's layer and basal epithelial cells. In LASIK sub basal nerve bundles and superficial stromal nerve bundles in the flap interface are cut by the microkeratome or femtosecond laser, with only nerves entering the flap through hinge region being spared. Subsequent excimer laser ablation severs further stromal nerve fiber bundles. Therefore, corneal sensation can lead to a reduction in the blink rate, resulting in epitheliopathy due to the increased ocular surface exposure and dry eye. [12,13] While there are also other factors, it is generally accepted that corneal denervation is the largest factor. [14,15]

SMILE & Corneal Biomechanics: The biomechanical strength of the cornea is greater in its anterior layer due to stronger intralamellar collagen bonding, and SMILE results in minimal disruption of peripheral collagen fibers resulting in relatively better corneal biomechanics. [16,17]Whereas in LASIK and PRK, the anterior stromal lamellae are severed by the excimer laser ablation and additionally by flap creation in LASIK, must leave the cornea with lesser biomechanical strength than SMILE. Also, extended range of treatment is possible due to better spherical aberration control as a result of better biomechanics.

Additionally, factors such as ambient air quality, temperature, and humidity are not as important for SMILE in comparison to LASIK with respect to refractive outcomes. The refractive predictability with the ReLEx procedure is better than with an excimer laser, especially for higher amounts of refractive errors.

SMILE and Astigmatism

In ReLEx SMILE procedure, the potential sources of torsional errors could be static cyclotorsion due to change in position from upright to supine, application of suction, speculum insertion, and squeezing of the eye during docking, and hence, it may be important to compensate for these cyclotorsional errors especially in higher degrees of astigmatism. Studies aiming at evaluating the outcomes of astigmatism correction comparing LASIK with SMILE showed superior outcomes with LASIK.[18,19,20]Furthermore, studies by Kunert et al. and Sekundo et al. showed a significant under correction of astigmatism with both FLEx and SMILE procedures respectively. [2,21]

The probable explanation of these results could be the lack of an active eye-tracking software in the VisuMax femto laser system. Since no definite method of cyclotorsion compensation exists for ReLEX SMILE, this may also be considered a potential limitation of this procedure at present. Previous studies on LASIK suggested that manual markings were equally safe and effective as the automated dynamic eye trackers for cyclotorsion compensation during the surgery.[22] Based on these observations, our group attempted to investigate the feasibility of manual compensation of the intraoperative torsional error using limbal markings as a guide, in patients with significant myopic astigmatism undergoing ReLEx SMILE. Figure 3 shows the

method of intraoperative cyclotorsion compensation followed in our study. In our prospective study, manual compensation of cyclotorsion error resulted in favorable outcomes in patients with myopic astigmatism treated with ReLEx SMILE. Results were analyzed by categorizing the data into two groups of low (-0.75—1.50D) and high (>-1.51D) astigmatism. It was observed that the predictability and accuracy of cylinder correction were better in eyes with high astigmatism compared to low astigmatism.[23] Based on the results of this study, preoperative limbal marking for all eyes with astigmatism of 1.5 D or more and manual compensation of cyclotorsion was recommended.

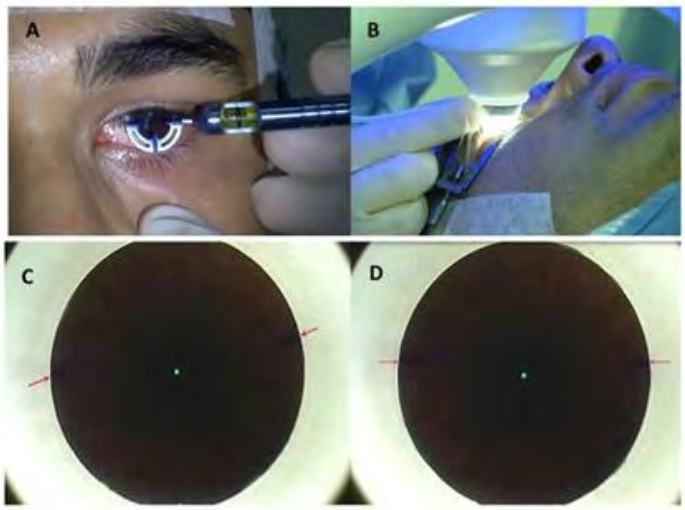

Figure 3 (a) Preoperative limbal marking with the Gerrish bubble marker (Epsilon Surgical, Irvine, CA, USA). This instrument uses the marks on the limbus at 0°, 90°, and 180°, extending 2 mm toward the center of the cornea, which are easy to visualize while the eye is being docked. (b) Method of manual cyclotorsion compensation by a gentle rotation of the cone while holding the same at the diameter of the tube of the cone. (c) Position of the limbal marks (red arrows) under suction "ON" position without cyclotorsion compensation before starting the laser, showing approximately 12° of cyclotorsion. (d) Final position of the limbal marks after manual compensation of the cyclotorsion error (aligned with the horizontal axis of the eye at the slit lamp). Delivery of the laser follows this (reproduced the permission from Journal of Refractive Surgery)

LIMITATIONS

There are few limitations of this procedure such as absence of an active eye-tracking mechanism, its inability to perform wavefront-guided or topography-guided treatments and induction of total higher order aberrations.

Retreatment, hyperopia, mixed astigmatism treatments are not approved yet. However; Hyperopia treatment is currently being studied. Preliminary results for hyperopia SMILE are encouraging, however, long-term data on the safety and efficacy of hyperopic SMILE are awaited until the software is available for commercial use.

COMPLICATIONS

Studies have reported a low incidence of complications related to SMILE. Since the procedure can be technically challenging, compared to LASIK/PRK most of the complications have been reported to have occurred early in the learning curve.Intraoperative complications such as suction loss during docking, black spots due to meibomian secretions, epithelial abrasions, small tears at the incision and cap perforation, Lenticule stuck on the cap, and difficult lenticule extraction.

Postoperative complications include trace haze, epithelial dryness in the immediate post-operative period and interface infiltrates.

Another complication unique to SMILE is the presence of a lenticule remnant in the interface due to inadvertent tearing of lenticule during its removal. Surgical exploration to remove the lenticule remnant can be done or topography guided PTK/ PRK can also be attempted to correct the irregular astigmatism.In our experience, it may be possible to extract such retained pieces of lenticules as late as 9 months of the failed primary SMILE procedure.

VISUAL RECOVERY AND ENERGY OPTIMISATION IN SMILE

Visual recovery has been found to be slower in SMILE as compared with LASIK especially in the hands of an inexperienced surgeon. This has been attributed to multiple factors such as increased surgical manipulations to remove the lenticule and micro distortions in Bowman membrane. With increase in experience of the surgeons who become more competent to smoothly manoeuvre the lenticule, causing lesser trauma to the surrounding tissues early visual recovery can be achieved.

In our experience with optimised laser, uniform bubble pattern is delivered after adjusting the energy and spot spacing pattern and thus maximize the ease of tissue separation. An ideal bubble pattern should be uniform in distribution and should be devoid of dense white spots(opaque bubble layer)or dark spots which could be due to use of very low energy close to plasma threshold. Another cause of dark spots is the presence of meibomian secretions, debris or fibers on the surface of the contact glass. If there is opaque bubble layer (OBL) present, this means that the energy is too high and the ease of dissection should be improved by incrementally reducing the energy.

The research into energy and spot spacing settings has led to the conclusion that lenticule surface regularity and visual outcomes are optimized by using lower energy and wider spot spacing. Lower energy reduces the size of the bubbles, while wider spot spacing reduces the chance of bubbles coalescing to form OBL. These two factors combine to maximize the lenticule surface quality and regularity.[24,25]

The quality of the interface is much more important in SMILE than in LASIK for the obvious reason that the interfaces in SMILE define the stromal tissue that is removed to induce the refractive correction. Therefore, it is to be expected that visual outcomes will be improved when the lenticule surfaces are more regular.[26]

RE-TREATMENT AFTER SMILE

There are many options for performing re-treatments after SMILE. The choice is often dictated by the primary cap thickness and the availability of the technology. The cap may be converted

into a flap and a thin-flap LASIK procedure may be performed. PRK may also be performed to re-treat SMILE patients.

USES OF SMILE LENTICULE

The lenticule obtained from SMILE as its by-product can be used in the management of keratoconus by inserting them into the lamellae at fixed depth followed by corneal collagen cross linking. The lenticules can be used to seal corneal perforations.

The lenticule can be used for potential treatment of moderate-to-high hyperopia through a procedure called femtosecond intrastromal lenticule implantation (FILI).[27]In this procedure, a SMILE lenticule matched for the recipient's refractive error was inserted into an intrastromal pocket created into the recipient's cornea.

CONCLUSION

The evolution of SMILE has introduced a new method for LVC. SMILE being a surgeon-based procedure involves a learning curve, which can be negotiated by ensuring good docking, optimizing energy levels, and gentle tissue handling. Outcomes may be further refined by developing surgeon-specific nomograms and manual cyclotorsion compensation. Although the outcomes of SMILE have been shown to be similar to LASIK in terms of safety and predictability, evidence is increasing that SMILE may be better than LASIK in terms of corneal biomechanics, postoperative dry eye and long-term stability of correction for high myopia.

REFERENCES

1. Sekundo W, Kunert K, Russmann C, Gille A, Bissmann W,Stobrawa G, et al. First efficacy and safety study of femtosecondlenticule extraction for the correction of myopia: Six-month results. J Cataract Refract Surg 2008;34:1513-20.

2. Sekundo W, Kunert KS, Blum M. Small incision corneal refractive surgery using the small incision lenticule extraction (SMILE)procedure for the correction of myopia and myopic astigmatism: Results of a 6 month prospective study. Br J Ophthalmol 2011;95:335-9.

3. Kurtz RM, Horvath C, Liu HH, Krueger RR, Juhasz T. Lamellar refractive surgery with scanned intrastromal picosecond and femtosecond laser pulses in animal eyes. J Refract Surg.1998;14(5):541-548.

4. Heisterkamp A, Mamom T, Kermami O, et al. Intrastromal refractive surgery with ultrashort laser pulses: in vivo study on the rabbit eye. Graefes Arch Clin Exp Ophthalmol. 2003;241(6):511-517.

5.Reinstein DZ, Archer TJ, Gobbe M. Small incision lenticule extraction (SMILE) history, fundamentals of a new refractive surgery technique and clinical outcomes. Eye Vis (Lond) 2014;1:3.

6.Pande M, Hillman JS. Optical zone centration in kerato-refractive surgery. Entrance pupil center, visual axis, coaxially sighted corneal reflex, or geometric corneal center? Ophthalmology1993;100:1230-7.

7.Vetter JM, Holzer MP, Teping C, Weingärtner WE, Gericke A,Stoffelns B, et al. Intraocular pressure during corneal flap preparation: Comparison among four femtosecond lasers in porcine eyes. J Refract Surg 2011;27:427-33.

8. Tian Han, Ke Zheng, Yingjun Chen, Yang Gao, Li He, Xingtao Zhou.Four-year observation of predictability and stability of small incision lenticule extraction: BMC Ophthalmology2016;16.

9.Kamiya K, Igarashi A, Ishii R, et al. Early clinical outcomes, including efficacy and endothelial cell loss, of refractive lenticule extraction using a 500 kHz femtosecond laser to correct myopia. J Cataract Refract Surg 2012;38:1996–2002.

10. He J, Bazan NG, Bazan HE: Mapping the entire human corneal nerve architecture. Esp Eye Res 2010, 91:513-523.

11. Tuisku IS, Lindbohm N, Wilson SE, Tervo TM: Dry eye and corneal sensitivity after high myopic LASIK. J Refract Surg 2007, 23:338-342.

12. Wilson SE: Laser in situ keratomileusis-induced (presumed) neurotrophic epitheliopathy. Ophthalmology 2001, 108:1082-1087.

13. Savini G, Barboni P, Zanini M, Tseng SC: Ocular surface changes in laser in situ keratomileusis-induced neurotrophic epitheliopathy. J Refract Surg 2004, 20:803-809.

14. Solomon R, Donnenfeld ED, Perry HD: The effects of LASIK on the ocular surface. Ocul Surf 2004, 2:34-44.

15. Shtein RM: Post-LASIK dry eye. Expert Rev Ophthalmol 2011, 6:575-582.

16. Shetty R, Francis M, Shroff R, et al. Corneal Biomechanical Changes and Tissue Remodeling After SMILE and LASIK. Invest Ophthalmol Vis Sci. 2017;58(13):5703–5712.

17. Chen M, Yu M, Dai J. Comparison of biomechanical effects of small incision lenticule extraction and laser-assisted subepithelial keratomileusis. Acta Ophthalmol. 2016;94(7): e586–e591.

18. Khalifa MA, Ghoneim AM, Shaheen MS, Piñero DP. Vector analysis of astigmatic changes after small-incision lenticule extraction and wavefront-guided laser in situ keratomileusis. J Cataract Refract Surg 2017;43:819-24.

19. Chan TC, Ng AL, Cheng GP, Wang Z, Ye C, Woo VC, et al. Vector analysis of astigmatic correction after small incision lenticuleextraction and femtosecond-assisted LASIK for low to moderate myopic astigmatism. Br J Ophthalmol 2016;100:553-9.

20. Zhang J, Wang Y, Chen X. Comparison of moderate- to high astigmatism corrections using waveFront-guided laser in situ keratomileusis and small-incision lenticule extraction. Cornea2016;35:523-30.

21. Kunert KS, Russmann C, Blum M, Sluyterman VL. Vector analysis of myopic astigmatism corrected by femtosecond refractive lenticule extraction. J Cataract Refract Surg 2013;39:759-69.

22. Shen EP, Chen WL, Hu FR. Manual limbal markings versus iris registration software for correction of myopic astigmatism by laser in situ keratomileusis. J Cataract Refract Surg 2010;36:431-6.

23. Ganesh S, Brar S, Pawar A. Results of intraoperative manual cyclotorsion compensation for myopic astigmatism in patients undergoing small incision lenticule extraction (SMILE). J Refract Surg 2017;33:506-12.

24. Donate D, Thaeron R. Lower energy levels improve visual recovery in small incision lenticule extraction (SMILE). J Refract Surg. 2016;32(9):636-642.

25. Ji YW, Kim M, Kang DSY, et al. Lower laser energy levels lead to better visual recovery after small incision lenticule extraction: prospective, randomised clinical trial. Am J Ophthalmol. 2017;179:159-170.

26. Reinstein DZ, Archer TJ, Carp GI. The surgeon's guide to SMILE. 2018:177-201.

27.Ganesh S, Brar S, Rao PA. Cryopreservation of extracted corneal lenticules after small incision lenticule extraction for potential use in human subjects. Cornea 2014; 33:1355-62.

Phacoemulsification in Small Pupil

Dr. Suven Bhattacharjee, MS, DO, DNB, FRF.

Nayan Eye Centre, Kolkata

E-mail: suvenb@gmail.com

Phacoemulsification in eyes with a preoperative or intraoperative non-dilating small pupil, is fraught with complications [1,2]. Understanding the small pupil is key to optimizing strategies to deliver better outcomes.

Every eye is a potential IFIS candidate; surgeons must reduce their threshold for using pupil expansion devices.

Most surgeons are skilled to performed safe surgery through a 5 – 6 mm pupil, provided the pupil does not get smaller unpredictably. A pupil device improves results by removing that element of unpredictability. Since its original association with tamsulosin intake, Intraoperative Floppy Iris Syndrome (IFIS) has been positively correlated with a plethora of risk factors which include: gender, age, hypertension, other a1-adrenergic receptor antagonists, finasteride, angiotensin II receptor inhibitors, benzodiazepines, antipsychotics, hypertension drugs and decreased dilated pupil diameter [1,3,4].The risk of IFIS exists regardless of alpha antagonist treatment, in eyes with 7.0 mm or smaller pupil [5].Hence, it would be prudent to consider every eye a potential IFIS candidate. Increased patient expectations, surgeon's desire to consistently deliver good outcomes, use of toric and premium lenses, and the availability of user-friendly pupil expanders have reduced the surgeon's threshold to use one [6].In IFIS, neither Iris Hooks nor Pupil Expanders can prevent Iris prolapse. (Fig 1)These pupil expansion devices provide a valuable constant pupil size allowing adequate visibility for safe phacoemulsification. Iris prolapse in a particular case depends on the severity or grade of IFIS and is not a measure of the efficacy of the device used. The severity of IFIS depends on the extent of pathological damage to the stroma and muscles of the Iris.

RELEASE POSTERIOR SYNECHIAE & PERIPUPILLARY MEMBRANES COMPLETELY

Releasing the posterior synechiae and peeling the peri-pupillary membrane [7,8] followed by intracameral injection of combination mydriatics and/ or viscoelastic may dilate the pupil adequately. It is important to sweep the spatula under the Iris to release extensive or total posterior synechiae [9] which may be tying down the Iris to the lens capsule.

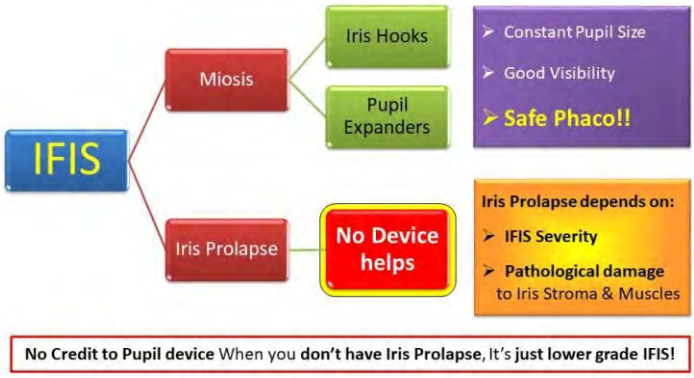

INTRACAMERAL INJECTION OF COMBINATION MYDRIATICS AND LOCAL ANAESTHETICS

Intracameral use of combination of epinephrine and lidocaine in fortified BSS as well as a combination of cyclopentolate, phenylephrine, and lidocaine has been shown to provide effective dilatation [10].However, these "homemade" cocktails can lead to dilution errors and accidental use of medications containing preservatives, which can lead to toxic anterior segment syndrome [11,12,13]. Currently, commercially available combination drug products are Omidria (Omeros Corporation], Mydrane (Thea Pharmaceuticals Limited) and Phenocaine Plus (Entod International).

INFLATION TEST: IDENTIFY THENON-ELASTIC RIGID PUPIL AND PREPARE IT FOR PUPIL DEVICE PLACEMENT

Unlike with non-elastic miotic pupils, the IFIS pupil immediately snaps back to its original size following attempts at stretching it [14]. Which means, small pupils are of two types, elastic & non-elastic (rigid).

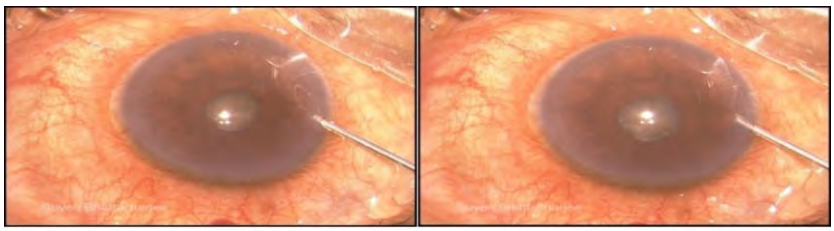

AC Inflation Test: Injection of BSS through paracentesis and inflation of the Anterior Chamber fails to expand the Non-elastic rigid pupil. The Fibrotic band at the pupil margin is visualized too.

An elastic pupil is expandable like a rubber band.(Fig 2) Whereas, a nonelastic rigid pupil is like a string and is not expandable but tearable. It will not expand until the pupil is stretched to tear the fibrous elements at the pupillary margin [15]. The elasticity of the pupil should be tested as soon as the paracentesis is made. As the anterior chamber (AC) is inflated with BSS, the elastic pupil expands momentarily and returns to its small size. On the other hand, a rigid pupil hardly enlarges. (Figs 3 & 4) It would be logical to assume that pupils undergoing intraoperative miosis are elastic in nature because they were reasonably dilated to start with.

ELASTICITY OF PUPIL & CHOICE OF PUPIL EXPANDER DEVICE: OVD/ IRIS HOOKS/ PUPIL EXPANDERS

In non-elastic pupils associated with pseudoexfoliation, the iris sphincter demonstrates fibrotic

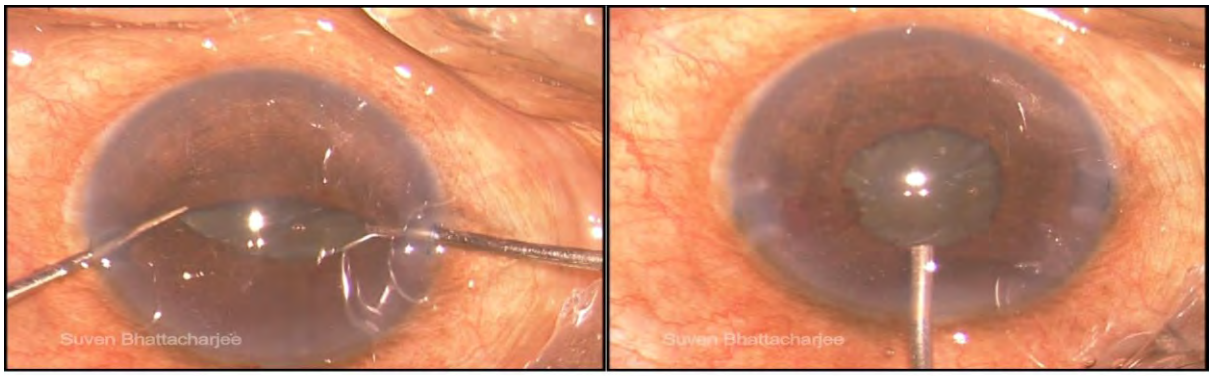

Inflation of Anterior Chamber with Viscolelastic after Bimanual Stretch with 2 Kuglen Hooks:
A Non-dilating rigid pupil is rendered expandable and favourable for Pupil device placement

Elastic Rubber Band
STRETCHABLE

Non Elastic String
TEARABLE

changes in the stromal and muscular elements [16,17]. For elastic pupils, ophthalmic viscosurgical devices (OVD), Iris hooks or Pupil expanders may be chosen depending on pupil

size, pupil co-morbidities and personal preference. However, rigid non-elastic fibrotic pupils can be expanded only after stretching or tearing the fibrotic sphincter at the margin with significant force either with two Kuglen hooks or with pupil expansion devices (Iris hooks or Pupil Expanders). When stretched bimanually to 5 mm with two Kuglen hooks in all directions, the stretching or tearing of the sphincter is symmetric and controlled, resulting in round pupils postoperatively. This facilitates the placement of any pupil expander device. If Iris hooks or Pupil Expanders are deployed in a non-elastic pupil without a prior bimanual stretch, the pupil is torn irregularly due to uncontrolled asymmetric stretching. A stiff and bulky device like the Malyugin Ring (Microsurgical Technology), I-Ring (Beaver-Visitec International) or APX 200pupil expander (APX Technology) may enlarge a rigid pupil but would be less maneuverable and cause uncontrolled disfiguring sphincter tears and glare [6,18,19].The hair thin 0.075 mm (75 micron) B-HEX Pupil Expander (Med Invent Devices) can easily expand an elastic pupil but requires prior stretching of a non-elastic rigid pupil [6,15,20]. A bulky device occupies more space in the AC and obstructs movement of instruments. The vertical profile of the Malyugin ring at the corner scrolls is 0.7 to 0.9 mm which is significant in the presence of a shallow AC because the scrolls occupy the mid-peripheral AC, which is shallower than the central part [21].The thinner B-HEX occupies very little space and allows unhindered instrument movement in the AC. The scrolls or pockets of some pupil expanders are thick biplanar structures. They snag the self-sealing slit corneal incision during entry and exit and require an injector to circumvent this problem. The thin profile and uniplanar design of B-HEX allow it to glide through much smaller incisions without an injector using a 23 gauge Microforceps [6]. A 5.5 mm pupil provided by a pupil expansion device is good enough for safe and effective phacoemulsification [6].A larger expansion requires a larger device which is unwieldy [6].With present technology and fluidics, an assurance that the expander would maintain a 5.5 mm pupil without collapsing, would encourage most surgeons to proceed with Phaco surgery [6]. Size for size, a hexagon is much more efficacious than a square and is safer and practical. Geometrically, between an equal sized square and hexagon having equal in circles, the square has a larger circum-circle. (Fig 5)Hence, a square device is more likely to injure the angle [6]. Apart from the additional incisions required, the additional operating time for iris hooks is more than that for pupil expansion rings [22].When introducing instruments into the AC, it must be kept in mind that Iris hooks elevate the pupil margin anteriorly to the limbal plane. Permanent changes to the

shape and/ or size of the pupil by damaging the iris sphincter is more common with Iris hooks compared to Pupil expansion rings [23].

VISCOMYDRIASIS

Healon 5 (2.3% sodium hyaluronate) has been found to be useful to achieve viscomydriasis in patients with a small or constricted pupil especially in patients with IFIS and an atonic iris [24].Viscomydriasis alone should be used with caution, as the limited duration of this effect will likely not last throughout phacoemulsification if other pupil-related pathologies exist [25].

GENERAL TECHNIQUES TO FACILITATE USE OF IRIS HOOKS & PUPIL EXPANDERS

Inflating the AC with viscoelastic flattens the iris against the lens capsule and makes it difficult to engage iris hooks or pupil expanders to the pupil margin. A deep AC would also require the devices to be inconveniently angled in an attempt to engage the pupil margin. It is preferable to keep the AC a little shallow and inject viscoelastic under the pupil margin so that the iris is bowing anteriorly and the pupil margin is lifted off from the anterior lens capsule [26].

IRIS HOOKS TIPS

A 0.5 mm incision is adequate to insert 4-0 or 5-0 Polypropylene or Nylon iris hooks. Larger incisions may leak and allow Iris prolapse. A mark to identify the incisions either by nicking the

conjunctiva or applying Trypan blue saves embarrassment as they can be very difficult to find. If a hook is to be placed at the phaco incision it should be planned well in advance. Limbal incisions beveled towards the endothelium help keep the Iris at a posterior plane. The stopper should be retracted in advance to allow the hook enough length to reach the pupil margin. Using the tented part of the pupil margin created by a previous hook to engage the subsequent hook, makes engagement of successive iris hooks much easier. Over retraction and asymmetric retraction of hooks is to be avoided. When used after a capsulorhexis, a second instrument or spatula may be used to tent up the pupil margin to ensure that the capsulorhexis margin is not engaged. In deep set eyes, the redundant part of the hooks beyond the stopper may be trimmed to allow unhindered movement of the eyeball and instruments.

Iris Hooks Removal: Withdrawing the stopper and then advancing the hook disengages it from

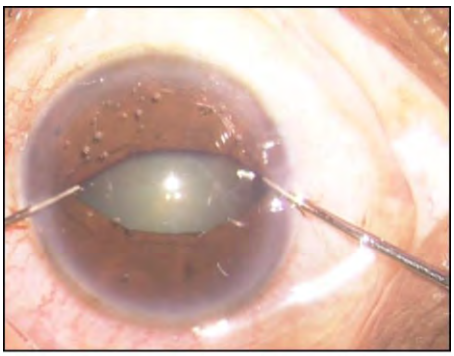

Buckled B-HEX: Bimanual Stretching with 2 Kuglen hooks along the long diagonal of the B-HEX-Pupil Complex

the pupil margin. Thereafter, the hook is simply pulled and it straightens momentarily as it traverses the paracentesis with no damage to the cornea.

PUPIL EXPANDER TIPS:

Malyugin Ring: It may be possible to engage the pupil margin into three scrolls in the first pass but this should not be an obsession because the success depends on the pupil size, WTW, AC depth, anterior lens contour etc. If the ring is lying on the iris, the possibility of endothelial touch should be considered because the scrolls are at the mid periphery where the AC is shallower than the centre. When the Malyugin ring is used after capsulorhexis, the gaps in the scrolls on the sides of the device are not directly visible in the top view. Aligning these gaps to the pupillary margin may be slightly difficult [21]. When the Malyugin ring is deformed during retraction, the scrolls can unpredictably crush or release the pupil margin. This is because the scrolls behave like a torsional spring and compression spring with narrowing of the gap as the arms are moved

towards each other and vice versa [21]. Pressing down on the scrolls with a spatula as they are retracted into the Injector tube prevents snagging of the scroll.

B-HEX Pupil Expander: The flanges should be held at the tabs with the tip of the jaws such that the tips of the jaws are within the outer limit of the flange. In other words, when tucking, the flange should be leading and not the Jaws. This allows the B-HEX to be carried to the maximum extent into the AC in the first pass without the jaws knocking the angle or the Cornea and the tucking is easier too.

Pre-stretching: If the Pupil is suspected to be non-elastic, stretching it to 5 mm is very helpful in engaging the B-HEX. In rigid pupils, the flanges can also be tucked bimanually using a 23-gauge forceps and a metal iris hook [21, 27]. If stretching is inadequate, it is often difficult to tuck the third flange. If it is tucked in the presence of a rigid pupil, the B-HEX buckles.

Difficulty in tucking 3rd flange of B-HEX: This happens when a rigid pupil has not been adequately stretched prior to engagement of the B-HEX. A safe remedy is to bimanually stretch the unengaged part of the pupil with 2 Kuglen hooks. Now the third flange can be tucked easily.

Buckled B-HEX resulting in smaller than 5.5 mm expanded pupil: This happens when the third flange of B-HEX is forcefully tucked in a rigid pupil which has not been stretched adequately prior to engagement. An easy remedy is to gently bimanually stretch the 'B-HEX-Pupil complex' with 2 Kuglen hooks along the long diagonal of the hexagon(Figure 6).The stretching should be gentle and only to the extent permitted by the circumference of the B-HEX. Or else, the B-HEX may lose shape or break.

B-HEX Removal: For removal through the main incision or side-port, the flange closest to the incision is held and the notches on either side are disengaged and the B-HEX may be drawn out. The trailing notches disengage spontaneously [6,26,28].

POST-OPERATIVE MEDICATIONS & FOLLOW UP

The use of pupil expansion devices may predispose eyes to increased risk of clinically significant Pseudophakic cystoid macular edema(CME) due to peri-operative manipulation of the iris. Effective anti-inflammatory treatment and follow-up are warranted in eyes with pupil expansion

device. [29] The possibility of CME must be kept in mind and OCT should be performed at the slightest suspicion.

SUMMARY

The elastic and non-elastic pupil needs to be differentiated. The choice of techniques and pupil expansion devices should be timely and judicious. The threshold for using a pupil expansion device should be very low because it could save serious complications.

REFERENCES

1. Al-Hashimi, Saba MD; Donaldson, Kendall MD, MS; Davidson, Richard MD; et al. J Cataract Refract Surg 2018 - Volume 44 - Issue 8 - p 1032-1041 doi: 10.1016/j.jcrs.2018.02.027
2. Malyugin B. Cataract surgery in small pupils. Indian J Ophthalmol. 2017;65(12):1323-1328. doi:10.4103/ijo.IJO_800_17
3. Christou CD, Tsinopoulos I, Ziakas N, Tzamalis A. Intraoperative Floppy Iris Syndrome: Updated Perspectives. Clin Ophthalmol. 2020;14:463-471. https://doi.org/10.2147/OPTH.S221094
4. Goyal S, Dalela D, Goyal NK, Chawla S, Dhesi R, Kamboj B, Dalela A. Intraoperative floppy iris syndrome in Indian population: A prospective study on incidence, risk factors, and impact on operative performance . Indian J Ophthalmol 2014;62:870-5. doi: 10.4103/0301-4738.141051
5. Casuccio A, Cillino G, Pavone C, Spitale E, Cillino S. Pharmacologic pupil dilation as a predictive test for the risk for intraoperative floppy-iris syndrome. *J Cataract Refract Surg*. 2011;37(8):1447-1454. doi:10.1016/j.jcrs.2011.02.030
6. Bhattacharjee S. B-HEX pupil expander: Pupil expansion redefined. Indian J Ophthalmol 2017;65:1407-10. doi: 10.4103/ijo.IJO_673_17
7. Osher RH. 2016, Nov 09. Peripupillary Membrane Removal: Video Journal of Cataract & Refractive Surgery. Retrieved from https://www.aao.org/clinical-video/peripupillary-membrane-removal
8. Devgan U, Rosatelli N. 2019, Sept 19. Synechiae & Small Pupil Cataract Surgery solved with the B-Hex ring. Retrieved from https://www.youtube.com/watch?v=o1xxEEi3LjQ&t=

9. Narankari M S, Khanna K K, Singh D, Chawla G D. Ciliary synechia. Indian J Ophthalmol 1971;19:169-71. PMID: 15745414

10. Myers WG, Shugar JK. Optimizing the intracameral dilation regimen for cataract surgery: prospective randomized comparison of 2 solutions. *J Cataract Refract Surg*. 2009;35(2):273-276. doi:10.1016/j.jcrs.2008.11.002

11. Srinivasan, Sathish FRCSEd, FRCOphth, FACS. Intracameral mydriatics during cataract surgery, Journal of Cataract & Refractive Surgery: March 2018 - Volume 44 - Issue 3 - p 257-258 doi: 10.1016/j.jcrs.2018.03.007

12. Mamalis, Nick MD Intracameral medication: Is it worth the risk?, Journal of Cataract & Refractive Surgery: March 2008 - Volume 34 - Issue 3 - p 339-340 doi: 10.1016/j.jcrs.2008.01.001

13. Bielory, Brett P. MD; Shariff, Ayesha MD; Hussain, Rehan M. MD; Bermudez-Magner, Jose Antonio MD; Dubovy, Sander R. MD; Donaldson, Kendall E. MD, MS Toxic Anterior Segment Syndrome, Cornea: May 2017 - Volume 36 - Issue 5 - p 621-624 doi: 10.1097/ICO.0000000000001145

14. Chang, David F. MD∗; Campbell, John R. MD Intraoperative floppy iris syndrome associated with tamsulosin, Journal of Cataract & Refractive Surgery: April 2005 - Volume 31 - Issue 4 - p 664-673

15. Bhattacharjee S. 2020, May 30.Elastic & Rigid Small Pupils and Choice of Pupil Expander: B-HEX is Always a Good Choice. Retrieved from https://www.youtube.com/watch?v=GCHYkMMevzs&feature=youtu.be

16. Repo, L.P., Naukkarinen, A., Paljärvi, L. *et al.* Pseudoexfoliation syndrome with poorly dilating pupil: a light and electron microscopic study of the sphincter area. *Graefe's Arch ClinExp Ophthalmol* **234,** 171–176 (1996). https://doi.org/10.1007/BF00462029 (Link)

17. Naoko Asano, Ursula Schlötzer-Schrehardt, Gottfried O.H. Naumann,A Histopathologic Study of Iris Changes in Pseudoexfoliation Syndrome, Ophthalmology, Volume 102, Issue 9, 1995, Pages 1279-1290, ISSN 0161-6420, https://doi.org/10.1016/S0161-6420(95)30873-1. (Link)

18. Chang DF. Use of Malyugin pupil expansion device for intraoperative floppy-iris syndrome: results in 30 consecutive cases. *J Cataract Refract Surg*. 2008;34(5):835-841. doi:10.1016/j.jcrs.2008.01.026 (Link)

19. Masket, Samuel M.D.[a] Relationship between postoperative pupil size and disability glare, Journal of Cataract & Refractive Surgery: September 1992 - Volume 18 - Issue 5 - p 506-507 doi: 10.1016/S0886-3350(13)80107-1 (Link)

20. Tripathy K, Majumdar S. Pupil expansion devices and mechanical stretching of the pupil. American Academy of Ophthalmology, EyeWiki. May 2020. https://eyewiki.aao.org/Pupil_expansion_devices_and_mechanical_stretching_of_the_pupil

21. Bhattacharjee S. Pupil-expansion ring implantation through a 0.9 mm incision. *J Cataract Refract Surg*. 2014;40(7):1061-1067. doi:10.1016/j.jcrs.2014.05.003 (Link)

22. Nderitu P, Ursell P. Iris hooks versus a pupil expansion ring: Operating times, complications, and visual acuity outcomes in small pupil cases [published correction appears in J Cataract Refract Surg. 2019 Feb;45(2):257]. *J Cataract Refract Surg*. 2019;45(2):167-173. doi:10.1016/j.jcrs.2018.08.038 (Link)

23. Akman A, Yilmaz G, Oto S, Akova YA. Comparison of various pupil dilatation methods for phacoemulsification in eyes with a small pupil secondary to pseudoexfoliation. *Ophthalmology*. 2004;111(9):1693-1698. doi:10.1016/j.ophtha.2004.02.008 (Link)

24. Osher RH. 2016, Oct 26. Achieving Viscomydriasis with Healon5. Video Journal of Cataract & Refractive Surgery. Retrieved from https://www.aao.org/clinical-video/achieving-viscomydriasis-with-healon5

25. FreidlKB, Moster MR. Techniques for Managing a Small Pupil During Cataract Surgery. Glaucoma Today, March/ April 2013. (Link)

26. Bhattacharjee S. 2017, Dec 27. B-HEX & Small Pupil Practical Tips. Retrieved from https://www.youtube.com/watch?v=nU-WEQGG_wQ&t

27. Rosatelli N. COMMENTED SURGERIES #13 - B-HEX In Extremely Small Pupil. Retrieved from https://www.youtube.com/watch?v=eT_q7Vsf-Fc&t

28. Megur D. B Hex ring-- The 5 steps for easy insertion. Dr Deepak Megur. Retrieved from https://www.youtube.com/watch?v=x6lyF4rEGsU

29. Taipale C, Holmström EJ, Ilveskoski L, Tuuminen R. Incidence of pseudophakic cystoid macular edema in eyes with and without pupil expansion device. *Acta Ophthalmol*. 2019;97(7):688-694. doi:10.1111/aos.14007 (Link)

Pearls for Maximizing Outcomes with Premium Multifocal IOLs

Dr. Nitesh Bansal
Consultant Eye Surgeon
Santokba Durlabhji Memorial Hospital, Jaipur
E-mail: nitesh_here@yahoo.co.in

In today scenario, cataract surgery has been converted into refractive cataract surgery due to patients enhanced expectations and new generation technology. Most of the patients want emmetropia for distance as well as for near also. This change of mindset in patients caused evolution of multifocal intraocular lens. These IOL's have multiple rings around the center of lens, which cause splitting of light and create multiple focal points and cover almost all distances like distance, near and intermediate also. This seems to be ideal, but the negative side is that these multiple focal points causes glare and halos, which creates lot of problems to the patients and post-operative dissatisfaction. In this article, the author share pearls for getting the best outcome after cataract surgery and multifocal IOL.

PATIENT SELECTION AND COUNSELING

Achieving a total or minimal spectacle independence with IOL's is not easy task and require an accurate IOL power calculation therefore proper patient selection, counseling remains the most important step regarding multifocal lens. Because these patients pay more, definitely they are more demanding. Always choose the patient with higher but realistic expectations, avoid fussy patients having extraordinary wishes. Never select the patient only upon his/ her paying capacity and patient demand, it should be according to patient profession and cataract work up profile. Always counsel the patient for both eye surgeries required one by one with minimum gap to get maximum results and minimize the glare and halos. These halos and glare reduce with time by neuro-adaptation phenomenon. Never promise the patient for no requirement of spectacles completely in future for any distance. Always tell the patient the there may be chances of

minimum glasses required for very far and very small near object. Overall the patient should have realistic expectations regarding the surgery. Try the fact *"under promise and over deliver".* Try to avoid these lenses in patients doing night driving frequently, professional drivers, pilots due to significant glare. Keep in mind that not every currently available IOL is suitable for every patient due to different routine activities and separate eye anatomy and physiology. These IOL's should be avoided in unilateral cataract.

PRE-OPERATIVE WORK-UP

The key of success is accurate and thorough workup in all cataract surgeries either monofocal, toric or multifocal. Multifocal lenses require slight more diagnostic tools apart from routine instruments. Detailed slit lamp examination should be done to rule out any central corneal opacity. Keep in mind that minor nebular corneal opacity in central area can finish the whole game. Any significant disease of the tear film must be treated before because meibomian gland dysfunction can greatly disturb patients postoperatively.

Proper history should be taken to assess the visual potential, rule out amblyopia and glaucoma or any finding that can hamper the visual outcome. Avoid cases like traumatic cataract, weak zonules or pseudo-exfoliation due the chances of decentration of IOL later. Pathological pupil is always a contraindication of multifocal lens. In unilateral cataract or already having monofocal lens in other eye, multifocal IOL should not be used ideally because for optimal visual outcome, the patient should have the same vision system in each eye.

Accurate biometry is must in all cases as post operative refractive error is not acceptable specially in premium multifocal lenses. K reading should be accurate either by gold standard manual keratometer or auto-refracto-keratometer or optical biometer or Pentacam. Best method is try to match the two reading with two different equipments. This gives you the extra confidence while putting in IOL formula. Avoid implanting a multifocal IOL in regular astigmatism more than 0.75 D, because this will produce significant blur and there is no predictable method available to correct the corneal astigmatism.

Axial length measurement can be done by ultrasound method (preferably immersion method) or optical biometer with fixation point. The beginner surgeon should avoid multifocal lenses in high myopes and high hyperopes as these patients have the chances of postoperative refractive surprises, which is not acceptable.

Precise IOL power calculation is very important for the successful visual outcome. Standard formulas can be used in relation to axial length. SRK-II works well in routine axial lengths, SRK-T in long eyes and Hoffer Q in short eyes can be used. Newer generation IOL formulas like Haigis and Holladay 2 or online Barrett Universal II formula can be used in extreme cases. But avoid these IOL's in extreme cases.

These IOL's are not suitable in patients having or chances of having retinal pathology in future like high myopia, diabetic retinopathy, uveitis, epiretinal membrane, etc. because the multiple rings in optical zone disrupt the visualization of fundus and create problems in laser treatment and vitreo-retinal surgeries.

ROLE OF THE OCT

Good macular function is necessary to get optimum outcome with any IOL, optical coherence tomography (OCT) is done to rule out any subtle macular pathology not detectable in fundus examination by ophthalmoscopy or slit lamp biomicroscopy. In multifocal IOL, we can't afford to miss anything abnormal in fovea so in few centers, OCT is a part of routine work up of all premium cataract surgeries.

ROLE OF CORNEAL TOPOGRAPHY/PENTACAM

Corneal topography provides necessary information about corneal optical quality, corneal astigmatism, corneal aberrations and keratoconus because suboptimal optics of cornea or post-operative refractive error may spoil the premium IOL implantation. In this era, we also get the patients undergone refractive surgery earlier. These patients can cause unpredictable results in terms of post operative refractive error and high order aberrations due to modified central corneal power . Topography or Tomography is the only tool to detect these cases and get dead centre corneal refractive power in cases like post Lasik, post PRK or post keratoplasty because it gives the corneal power of dead center of cornea. Also gives information about corneal spherical aberration in form of Z4 value, helps to select the aspheric platform of multifocal IOL. The normal cornea is prolate shaped, it means the steepest part in center of cornea, while periphery is having flatter part. After myopic lasik, cornea becomes oblate means centrally flat and steeper in periphery. So we have to use negative spherical platform according to Z4 value. In hyperopic

lasik, cornea becomes hyperprolate means more steeper in center and flat in periphery, so we can use normal conventional IOL or having lower negative sphericity.

It provides high order aberrations (HOA) information in the form of RMS value (Root Mean Square) in central 4mm zone. The cut off value is 0.35. If RMS value is >0.35, this can be the cause of dissatisfaction of patients when contrast sensitivity and visual acuity not improved as expected (Figure 1). The surgeon should avoid implanting multifocal IOL in patients having value more than 0.35. HOA value can also obtained by *iTrace* Aberrometer.

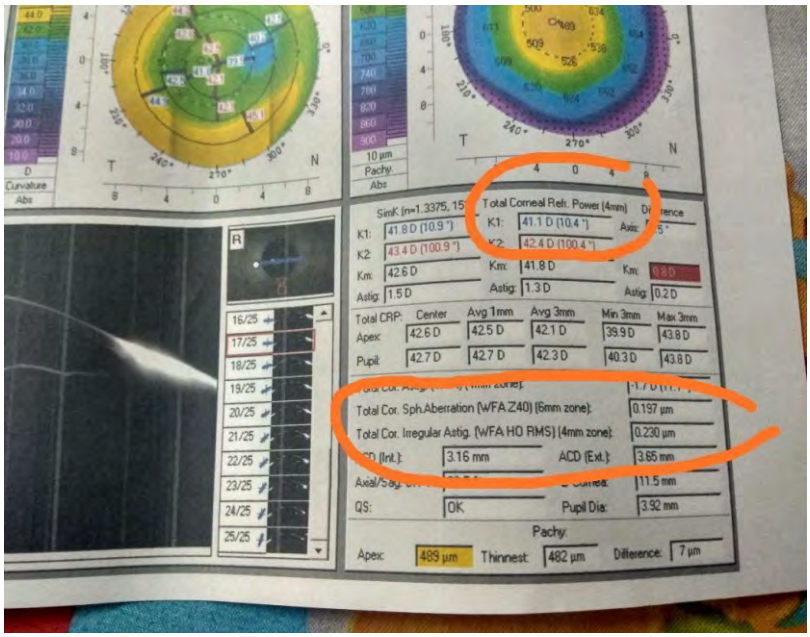

Figure 1. Showing Z4 and RMS value in Pentacam. Note Z4 value is 0.19 and RMS value is 0.23 in this patient.

ANGLE KAPPA

Multifocal lens blogs are incomplete without discussion about angle kappa. It is the angle between visual axis and pupillary axis. Visual axis coincides with the fovea and the sharpest vision can be obtained along this line (Figure 2). It is clinically important to the refractive surgeons because patients having large angle kappa characterize the center of the pupil does not match the point through which a fovea-centric ray of light passes. Thus, any treatment that is performed centered on the pupil results in a decentered ablation. This angle have importance in multifocal lens also, not in monofocal IOL because monofocal IOL does not have steps or rings on its surface. In multifocal IOL that is centered on the pupillary axis but not on the visual axis

with large angle kappa would hit the surrounding ring instead of central zone. This creates the photic phenomenon and patient would have lots of glare and always complains of not satisfying with the results.

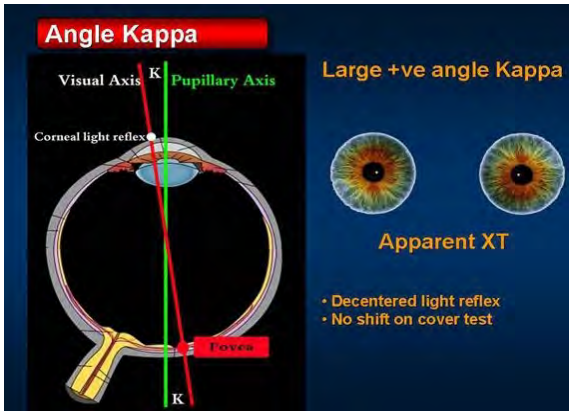

Figure 2. Angle kappa in normal eyes.

Normal values of angle kappa is less than 0.4 mm or <5 degree. It can be measured by synoptophore or more accurately with iTrace aberrometer (Figures 2-4). iTrace actually shows the image seen by patient before or after any eye surgery. So well centered IOL in the bag is not sufficient, but try to align the center of the lens along visual axis, if possible (along the Purkinje image just nasal to light reflex of the microscope). Avoid multifocal lenses in patients having large angle kappa like high hyperopia.

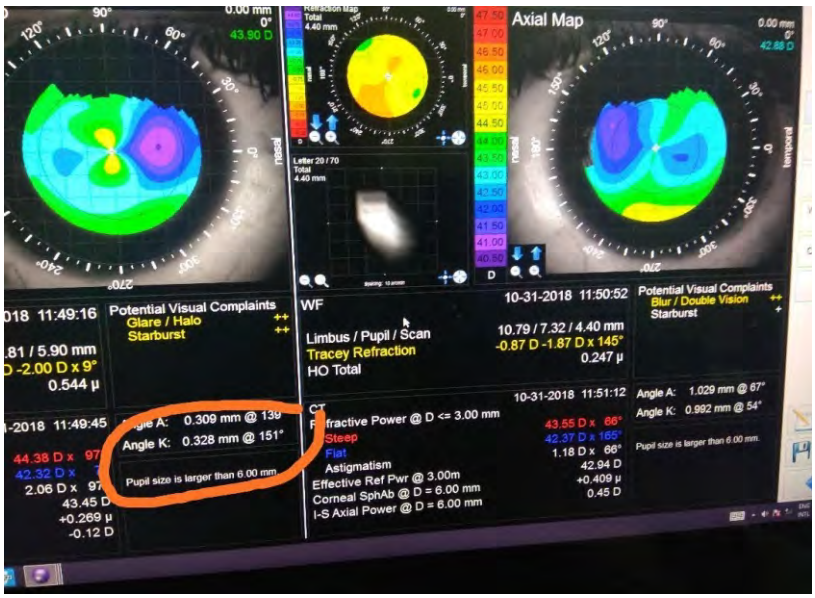

Figure 3. Illustrates angle kappa digital value in iTrace Aberrometer (Note angle kappa value is 0.32 mm).

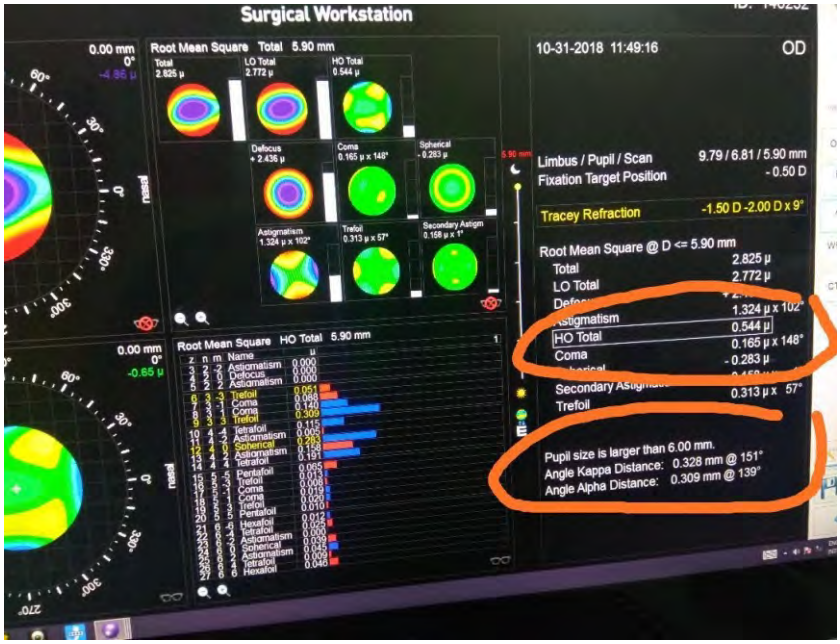

Figure 4. illustrates angle kappa value and HOA in iTrace. Note angle kappa value is 0.32 and HOA value is 0.54, this patient is not fit for multifocal IOL due to high HOA value).

CHOICE OF IOL

The IOL choice should be discussed during the counseling and according to the need of patient and independent of phaco-machine bundling but definitely it should depend upon operating surgeon ease, comfort and experience. There is always the importance of well centered around 5.5mm continuous capsulorhexis for IOL centration during surgery and after surgery. Do not put multifocal IOL in presence of intraoperative complications like posterior capsular rupture, zonular dialysis, descemet's detachment, pupillary damage. Always keep ready with spare monofocal lens of same power and implant in above or any other complication, if occurs. Use appropriate eye drops to prevent post operative cystoids macular edema and patient dissatisfaction.

CONCLUSION

The author shared the pearls for implanting the multifocal IOL. The basic idea is that patient selection should not be only based upon financial capability. We should do workup as much as possible to increase the visual outcome and our patients satisfaction. Always learn with your

previous experiences, our seniors and colleagues and create your own nomogram. After all *"Multifocal IOLs are a common reason for medical litigation."* Proper patient selection, good counseling, thorough workup, meticulous surgery and post operative follow up are the key of success.

REFERENCE

1. Chen Xu. Successful Premium Multifocal IOL Surgery: Key Issues and Pearls. March 5th 2021 DOI: 10.5772/intechopen.96182

Current Concepts in Ophthalmic Operating Room Sterilization

Dr. Rakesh Porwal, Dr. Payal Singh

Department of Ophthalmology, J.L.N. Medical College & Hospital, Ajmer

E-mail: dr.rakeshporwal@gmail.com

INTRODUCTION

Post-operative endophthalmitis and Toxic Anterior Segment Syndrome (TASS) being a sight-threatening complications of any intraocular surgery are the worst nightmare for an ophthalmologist. The medical device or the surgical instrument that comes in contact with the sterile tissue or the mucus membrane of the patient during the various processes is associated with increased risk of introduction of pathogens into the patient's eye. Moreover, there is chance of transmission of infection from patient to patient, from patient or to health care personnel, and vice versa; or from the environment to the patient through the improper sterilized or disinfected devices. Hence, medical personnel, laboratory people and the health care providers should have better knowledge regarding these techniques to prevent the spread of these pathogens.

Aseptic technique is a collection of target specific practices and procedures, under controlled condition to prevent the transfer of pathogenic microorganism and thus maintaining the sterility of an object or area.

The source of these infections can be either endogenous or exogenous. In this article, the authors share the current concepts of sterilization of an ophthalmic operating room and will elaborate the potential sources of exogenous infection like etiquettes followed by the operation theatre (OT) personnel, air quality, instrument sterilisation etc.

LAYOUT AND DESIGN OF AN OPERATION THEATRE

One of the most important component of OT asepsis is its design and location. It is scientifically planned barrier system, such that the main flow of traffic is always from clean area to dirty. It consists of 4 different zones[1]:

A. Outer Zone

- Area for receiving patients relatives.
- Rooms for administrative staffs
- Toilets

B. Restrictive zone

- Changing room for staff
- Patient transfer bay
- Store rooms
- Nursing room
- Anesthetist room
- Recovery room

C. Aseptic Zone

- Preparation room
- Scrub area
- Operation theater
- Area for instrument packing and sterilization

D. Disposal Zone

Corridor for waste disposal and for cleaning of OT equipments.

CONCEPT OF MODULAR OPERATING ROOM

The most complex and challenging area of hospital construction is the operating department. The modular operating theatre integrated approach to the construction and co-ordination of operating theatre. The modular operating theatre offer the advantage of speedy construction combined with design, future expansion and development in surgical technique whilst simultaneously providing a structure of the highest quality and standards.

Modular OT is a finished steel structure with joint less sterile coating which provides very high quality finish. It offers speedy constructions, long durability and ease of maintenance.

Components of Modular OT:

Laminar Air Flow & AHU

Walls & Ceiling: The entire wall panels are made of stainless steel with antibacterial and antifungal paint. The ceiling also incorporates "high efficiency particulate air (HEPA) filter and laminar air-flow system. Paneling of Walls encloses the electric wires and outlets for OT exhaust. General OT lighting and illumination is incorporated in the ceiling. All the controls are available within the OT, audio visual alarm can also be installed.

Floors: It is generally anti-static vinyl and should be smooth and stain proof without any cracks/breaks .

Doors: Ideally should be spring loaded flap type but sliding doors or automatic doors can be preferred as no air currents are generated.

OT Pendants: These are wall or ceiling mounted which brings all electric wires and medical gas supply for all the equipments used during surgery. Each pendant may have vertical and lateral or rotator movement using double-arm system.

Pendants also provide:

- Data points
- Shelves for some equipment
- Drawers for accessories
- Support arms for mounting monitors, pumps, etc.
- Mounting of Medical Devices and others

Pressure Relief Damper: In order to prevent cross contamination of air from clean and dirty area, each room is provided with pressure relief damper. Suitable sized air pressure relief damper to be strategically placed, enabling differential room pressure to be maintained and ensure that when doors are opened between clean and dirty area.

Scrub Station: Should have foot- operated water tap or motion- sensor tap along with time display to encourage the surgeon to scrub for the necessary time period.

OT Control Panel: All the controls of modular OT is mounted on the wall of theatre. Meets the electrical safety codes for low and high voltage system.

Advantages of modular OT:

- Dust free installation
- Smooth surface which is easy to clean and disinfect
- Up gradation is easy
- Products used are generally recyclable

STERILIZATION OF OPERATION THEATRES

I. **Ventilation-Air Care-Air Handling Unit (AHU)**

Surgical area should be well ventilated and should have air filter. Its principle is to deliver positive pressure and laminar unidirectional air flow from cleaner area to less cleaner area. Following Table shows the recommended parameters for their respective titles.[2]

Table 1. Recommended parameters.

Air Changes	20 per hour, 10-20% fresh air change/hr
Air Velocity	25-35 FPM (feet per minute), unidirectional and downwards on the OT table
Minimum positive pressure	2.5 Pascal, maintains positive pressure difference between OT and adjoining areas to prevent entry of outside air into OT.
Temperature	(18-24) ^{0}C
Relative humidity	20 to 60%[
HEPA filter	99.97% efficient, removes particle as small as 0.3micron.

II. Cleaning

Cleaning is the first and very important step before any disinfection measure. Removes visible dirt, organic matter and reduces bacterial load.

Floors – First cleaned with detergents mixed with warm water followed by a disinfectant like eco-shield using Three Bucket Technique. It's better to never use broom as increases bacterial load by aerosol spread in the environment, wet pick is used instead

Cleaning of roof is recommended only when remodeling or accumulation of dust. Ceiling fans are not recommended in OT.

In between cases, spot cleaning (with 10% eco-shield) of operation tables, theatre equipment should be done.In case any spillage of blood/body fluids occurs, chloride solution can be used for cleaning.

Biomedical Wastes should be discarded in prescribed plastic bags. Soiled gowns and OT linens must not be left unattended in the operation theatre.

At the end of the day's schedule table tops, door handles should be cleaned with detergent / low level of disinfectant, floors with detergents mixed with warm water and finally mopped with disinfectant like Phenol in the concentration of 1 : 10 Uni-directionally. [Table 2][3]

Table 2. Cleaning of the Operation Theatre.

Disinfectant	Area	Frequency
2% Bacillocid	Walls	Twice daily
	Roof	Every 3 months
	Floor	Twice daily
Sodium Hypochlorite	Sink	Once daily
Water	AHU & Pre-filters	Every 3 months
Alcohol based spray	Furnitures of OT	Once daily

III. Disinfection

Disinfection describes a process that eliminates most, if not all, pathogenic microorganisms, except bacterial spores. Disinfectants are generally classified as follows.

a. High level disinfectants: Chemicals that kill all microorganisms except bacterial spores, when exposed for limited time. Germicides categorized as chemical steriliants are high level disinfectants. These include 2.4% glutaraldehyde based formulations, 0.94% glutaraldehyde with 1.64% phenol, 7.5% stabilized hydrogen peroxide, 7.35% hydrogen peroxide with 0.23% peracetic acid, 0.8% peracetic acid with 1% hydrogen peroxide.

b. Intermediate level disinfectants: They kill mycobacteria, vegetative bacteria, most viruses and most fungi but do not necessarily kill bacterial spores. Phenolics, alcohols, iodophors and chlorine-based agents act as intermediate level disinfectants.

c. Low level disinfectants: Can kill most vegetative bacteria, some fungi and some viruses. Commonly used detergents and soaps act as low level disinfectants along with their cleaning properties. It is a process which reduces the number of pathogenic microorganism to the point where they no longer cause diseases.

A). Chemical Disinfection

Formaldehyde Fumigation- Formalin solution is heated, fumes generated inactivates the microorganisms by alkylating the amino acid and sulfhydryl groups of protein structure of microorganisms. OT is left unentered overnight followed by neutralization of formalin fumes by ammonia next morning(for 2-3hrs). 500 ml of 40% formaldehyde in one liter of water and 300ml

of 10% ammonia is required for per 1000 cubic feet. But due to its carcinogenic effect its uses is questionable .

Other disinfectant:

- Baccilocidrasant: Formaldehyde-free disinfectant. It contains Glutaral,benzyl-C12-18-alkyldimethylammonium-chlorides, didecyldimethyl -ammonium chloride . It has the ability to achieve complete asepsis within 30-60 minutes.
- Eco-shield/ Baccishield: Mixture of Stabilized hydrogen peroxide 11% w/v &0.01% w/v silver nitrate solution.
- Aldekol: 6% formaldehyde, 6% glutaraldehyde and 5% benzalkonium120 chloride.

B) Ultraviolet Radiation

Ultraviolet irradiation has been found to be germicidal in the range of wavelength 100- 254 nanometers(UV-C range), thus effective in reducing the risk of surgical site infection including MRSA.[4-6] Photokeratitis is its ocular hazard.[7] Done Daily for 12 -16 hrs. To be switched off 2 hours before entering OT.

STERILIZATION OF INTRAOCULAR SURGICAL INSTRUMENTS

I. Decontamination of equipments: Immediately after use, all surgical instruments that have been in contact with body fluids should be placed in a solution of 0.5% chlorine for 10 minutes then rinsed with water.

II. Cleaning of equipments: Can be done either manually or mechanically. The instruments should be scrubbed in lukewarm water with detergent to remove any residue. Ultrasonic cleaner (solution- Chlorhexidine & Cetrimide) can also be used for micro surgical instruments and instruments with hinged areas and serrated edges, other devices which has lumen such as phaco or irrigation & aspiration cannula. Instruments are then dried with air drying machine or fibre free cloth as it minimizes risk of re-contamination & reduces staining and rusting.

III. Packaging

It is done to prevent further contamination by dust and microorganisms.

IV. Sterilization

A process that removes, kills or deactivates all forms of micro-organisms & biological agents.

A) **Autoclave**: Steam Under Pressure. It kills bacteria, viruses, fungi, and spores on items when placed inside a pressure vessel and heated to an appropriate sterilization temperature for a given amount of time. Recommended temperatures for steam sterilization are 121° C for 30 min at 15 lbs psi pressure, 132°C or 135° C for 14 min.[8]

Table 3: Horizontal autoclave versus vertical autoclave.

Horizontal Autoclave	**Vertical Autoclave**
200 liters of water in two baskets	2500 liters of water in two vertical baskets
Time required for heating and cooling is much less	More time required for heating and cooling
Steam consumption is less	Steam consumption is More
Door has a bayonet lock with steering wheel	Closing and opening of door demands big labor. I
Loading and unloading of baskets can be automated	Cannot be automated

Flash Autoclave: It is a process used for sterilizing unwrapped instruments for immediate use when emergency situation arises. It is of two types i.e. Gravity dependent autoclave and Pre-vacuum autoclave. It requires temperature of 132 ^{o}C for 3min(for non-porous items) & 10min (for porous items) at 27-28 lbs pressure in gravity. It should not be used as a substitute.

B) **Low Temperature Sterilization**: It is used for equipments those are heat & moisture sensitive.

Ethylene oxide: Commonly used for sharp objects. It alters DNA by alkylation and thus destroys the ability of microorganism to reproduce and metabolize. After loading the sterilizer, air is removed with vacuum followed by heating it to temperature 45-55°c for 12 hours if 5psi and 6 hrs if 10 psi later on gas is removed by vacuum and flushing with air is done

Hydrogen peroxide Plasma sterilization: It is highly ionized gas composed of electrons, ions & neutral particles. It is applicable to both living and non-living objects and is generated

when precursor gas or vapor of hydrogen peroxide or peracetic acid is introduced into a chamber under low-vacuum conditions then the gas or vapor is excited with microwave or radiofrequency energy[9]. Temperature for sterilization ranges between 37-44 ^{0}C & Time 38-52 min.

C) **Chemical Sterilization:** 2% Glutaraldehyde also known as CIDEX is used as chemical sterilizer and is suitable for instruments that cannot be autoclaved (sharp cutting instruments, plastic & rubber items). It is not used for instruments with lumen e.g. irrigating cannulae as the residual glutaraldehyde can causes ocular problems like corneal edema, endothelial cell damage and uveitis. It is effective against vegetative pathogens and resistant pathogenic spores. The time period effective for sterilization is 8- 10 hours. It should be replaced when solution becomes cloudy.

MONITORING OF STERILIZATION

A) **Operation Theatre**:

i. Microbial Monitoring- Swabs are taken on weekly basis from various locations of OT like OT tables, trolleys, all the walls, floors, microscope handle, refrigerator, surgeons & nurse gloves etc. Ideally OT validation should be done twice

ii. Evaluation of Air quality- It is done weekly by *Settle Plate Method* in which Blood agar & Sabouraud's agar culture plate is placed, lid of which is kept open for 30min then sent for culture and colony counts. If bacterial colony count is more than 10/plate & fungal colony count more than 1/plate then it is *unacceptable* and OT is closed immediately and should remain closed until the culture reports comes negative.

B) **Instruments**:

Indicators for the effectiveness of instruments sterilization are-

i. Mechanical Indicators includes time, temperature and pressure

ii. Biological Indicators like Geobacillus Stearothermophilus spores etc.

Table 4: Operation Theatre: Do's and Don'ts

Do's	**Don'ts**
Respect sterile zone	Do not touch sterile surface with unsterile hand
Always wear Scrub should in Clean Zone	Do not bring mobile, books inside the OT
Bare below elbow	Do not drop articles on the trolley
Wear cap and mask properly	Do not eat inside OT
Follow Hand Hygiene	Do not lean onto the surfaces
Wear OT sleepers	Do not open door with gloved hands
Remove Jewellery	Do not wear OT clothes over regular clothes
Clip nails short	Do not pinch nose over the mask
	Do not put bindi, kumkum

REFERENCES:

1. Rice NS, Harry J. Ophthalmic operating theatre design: methods of sterilization. Proc R Soc Med 1969; 62:1203-04.
2. Revised Guidelines for Air Conditioning in Operation Theatres – NABH-Air Conditioning OT (2018) Issue No. 4 Issue Date: 11/ 18 Page 1 of 6.
3. https://www.tnoajosr.com/viewimage.asp?img=TNOAJOphthalmicSciRes_2018_56_2_84_238501_t10.jpg
4. Hart D. Bactericidal ultraviolet radiation in the operating room. Twenty-nine year study for control of infections. *JAMA* 1960;172:1019-28.
5. Brown IW Jr., Moor GF, Hummel BW, Marshall WG Jr., Collins, JP. Toward further reducing wound infections in cardiac operations. *Ann Thorac Surg* 1996;62:1783-9.
6. Ritter MA, Olberding EM, Malinzak RA. Ultraviolet lighting during orthopedic surgery and the rate of infection. *J Bone Joint Surg* 2007;89:1935-40.
7. University of Rochester, Environmental Health and Safety: Industrial Hygiene Programs: UV Light. Ultraviolet light safety guidelines. Rochester, NY. September 21, 2009. Available at: http://www.safety.rochester.edu/ih/uvlight.html. Accessed April 28, 2010.
8. https://www.steris.com/healthcare/knowledge-center/sterile-processing/everything-about-autoclaves.
9. Vesley D, Langholz AC, Rohlfing SR, Foltz WE. Fluorimetric detection of a bacillus stearothermophilus spore bound enzyme, a D-glucosidase for rapid identification of flash sterilization failure. Appl. Environ. Microbial 1992; 58: 717-9.

Approach to the Management of Corneal Ulcer: A Review

Dr. Seema Meena, Dr. Aparna M, Dr. Kavita Bhatnagar, Dr. Nikhil Agrawal,
Dr. Kriti Jai Singh, Dr. Manjari Tandon, Dr. Jyoti Shakrawal
Department of Ophthalmology
AIIMS, Jodhpur, Rajasthan
E-mail: nikhil.aiims87@gmail.com

ABSTRACT

Corneal ulcers are the leading cause of corneal blindness in developing countries and pose a major challenge for treating physician due to their potential to develop severe sight treating complications. Therefore it is essential to understand the step wise management of different corneal ulcers. *This review aims to simply the diagnosis and management of infective corneal ulcers.*

INTRODUCTION

According to the National Programme for Control of Blindness (NPCB) estimates, there are currently 120,000 corneal blind persons in the country. There is addition of 25,000-30,000 corneal blindness cases every year in the country. 90% of the global cases of ocular trauma and corneal ulceration leading to corneal blindness occur in developing countries.(1)Corneal ulcer is considered as a leading cause of corneal blindness especially in the developing countries. It has been estimated that globally corneal ulceration with ocular trauma accounts to 1.5 -2 million cases of corneal blindness annually (1). The major reason for corneal ulcer is ocular trauma In developing countries like India, whereas in the developed countries, the most common reason is contact lens wear. In developing country like India cases of corneal ulcer are usually either undiagnosed or misdiagnosed. So it is essential to understand the approach to a case of corneal ulcer for proper management.

ETIOLOGY

Corneal ulcer could be as a result of infective or non-infective pathology. Infectious causes are depicted in the figure. Whereas the non- infectious causes include autoimmune, toxic, allergic keratitis, chemical burns, neurotrophic, keratitis secondary to entropion, trichiasis, blepharitis, lagophthalmos. In corneal ulcers of infective origin, bacterial corneal ulcers accounts to most of the cases .In India the most predisposing factor for a ulcer is injury(2). It is common in male population and farmers are especially at a high risk.. Infectious causes of corneal ulceration may vary based on geographic location. The common microorganism are Fusarium species, Pseudomonas Aeruginosa, Aspergillus, Streptococcus Pneumoniae, Staphylococcus. However in countries like India fungal organisms are quite common (Figure 1).

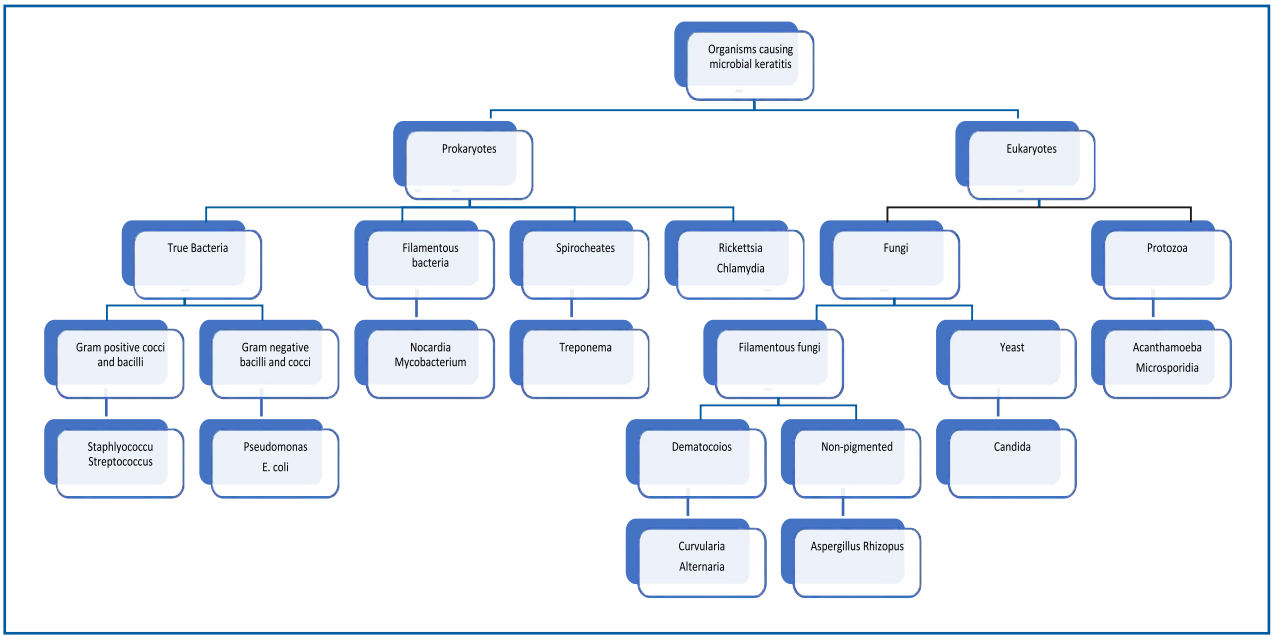

Figure 1: Micro-organism causing Microbial Keratitis.

APPROACH TO A CASE OF CORNEAL ULCER

1. History taking

A detailed history of symptoms and their duration should be elicited, and risk factors evaluation should be done. A corneal ulcer cannot develop in a healthy individual with a healthy ocular surface in the absence of ocular trauma. So a detailed history focused on finding the cause of an ulcer in the patient is of paramount importance to ensure appropriate management. History of

ocular surgery, ocular trauma, contact lens use, long-term use of ocular medications (topical steroids, Anti-glaucoma medications), and previous ocular infections is essential as these factors may change the ocular surface in the absence of trauma. Similarly, systemic diseases such as diabetes, rheumatoid arthritis, hepatitis, auto-immune diseases, tuberculosis, malignancy impair the natural immune status of an individual and predispose them to opportunistic infections, unusual microbes, fungi or viruses (Table 1, 2, 3).

Table 1: Differences between fungal and bacterial keratitis

	Bacterial	Fungal
Symptoms	Severe Rapid progression	Indolent course Signs >> Symptoms
Signs	• Mucopurulent discharge • AC reaction • Mobile hypopyon	• Feathery margin/hyphate edges • Rough + Dry • Satellite lesion • Fixed hypopyon • Immune ring of wessely

Table2 : Characteristic Features of different microbial Keratitis and features to differentiate them from sterile keratitis

Infectious keratitis	**Sterile keratitis**
1.Bacterial -Severe symptoms, epithelial defect with infiltration, mobile hypopyon	1.anterior basement membrane dystrophy-Recurrent epithelial erosions
2.fungal-Signs> symptoms, feathery margins, dry texture, fixed hypopyon, pigmentation, satellite lesions	2.neurotrophic ulcer- central oval epithelial defect with rolled out edges.

3.acanthamoeba- Contact lens, severe pain, ring ulcer, radial keratoneuritis	3.toxic keratitis- diffuse epitheliopathy (antibiotics, antiviral, anesthetics)
4.viral -Recurrence, epithelial (dendritic, geographic), stromal (immune ring, neovascularization), endothelitis, ↓corneal sensation	4.marginal keratitis (immune mediated- rheumatoid arthritis, Mooren ulcer)

Table 3: Difference between Herpes Simplex viral Keratitis and Herpes Zoster viral Keratitis

Features	HSV	VZV
Overall	Fine, lacy	Thick ropy
Epithelium	Linear defect with bared stroma with surrounding oedematous epithelial cells	Elevated with painted on appearance
Staining	Base stains with fluorescein and borders with Rose Bengal	Minimal fluorescein staining
Terminal bulbs	Frequent	None

Symptoms

The patient may present with the following symptoms.

- Pain: Pain is severe in the case of acanthamoeba ulcer due to the radial keratoneuritis or herpetic ulcers while less painful in case of fungal ulcers. Superficial ulcers are more painful than deep ulcers. Sometimes the patient may feel sudden relief of pain due to perforation.
- Redness and photophobia

- Discharge: may be watery in case of viral or small ulcers while mucopurulent in case of bacterial ulcers and greenish-yellow in pseudomonas.
- Diminution of vision: depending on the severity and location of the Ulcer, the patient may present with varied vision loss. Central ulcers and deep ulcers will result in more significant visual impairment. Associated hypopyon, cataract, glaucoma, endophthalmitis will also lead to reduced vision.
- Onset and progression of Ulcer
    - Sudden onset, rapid progression is associated with bacterial ulcers (staphylococcal aureus, pseudomonas, pneumococcus), while gradual onset, indolent course are found in fungal ulcers.

2. **External examination**: we should have a look at the general appearance of the patient, skin conditions, facial examination, eyelids and lid closure, corneal sensations

3. **Visual acuity**

4. **Intraocular pressure:** Digital tension should be checked as applanation being contact procedure is avoided.

5. **Slit lamp examination**

   A thorough slit lamp examination is helpful to evaluate the clinical signs, which may be helpful to confirm the probable diagnosis.

   - Tear film: look for dry eye or debris.
   - Eyelid: Meibomian gland disease, eyelash abnormality, nasolacrimal duct obstruction, or punctal anomalies
   - Conjunctiva: Discharge, erythema, follicles, papillae, cicatrization, keratinization, membrane, pseudomembrane, ulceration, scars, foreign bodies
   - Sclera: Inflammation, ulceration, nodules, ischemia, or thinning
   - Anterior Chamber reaction: Cell, flare, hypopyon, or fibrin

   Examination of Ulcer: it should be a detailed examination of the location, size, shape and margin of the Ulcer.

- Location: Central location in case of staphylococcal species, peripheral in case of HSV keratitis , Staphylococcal marginal keratitis, atypical mycobacterium, or peripheral ulcerative keratitis.
- Size: Ulcer is graded as small if it is less than 2mm, moderate if it is 2-5 mm and severe if it is more than 5 mm.
- Shape : feathery margin is characteristic of fungal Ulcer while dendritic, amoeboid or geographical ulcers are of viral etiology and oval in case of neurotrophic Ulcer.
- Margin: margins are well defined in case of healing ulcers and sterile ulcers, indistinctive in active ulcers, feathery in fungal and irregular in Acanthamoeba and undermining in Mooren's Ulcer.

Pictorial representation of the Ulcer is done to communicate better between the treating physician and monitor the progression or regression of the Ulcer.

7. Clinical Diagnosis

Careful slit-lamp assessment and clinical experience will help us to reach to a probable diagnosis. Bacterial keratitis: Epithelial defect with large infiltrate and conjunctival injection. Anterior chamber reaction may be present with associated lid swelling and chemosis. Staphylococcal keratitis: dense corneal infiltration with distinct borders with moderate AC reaction and hypopyon.[3] Streptococcal keratitis: Acute, purulent, and rapidly progressive with deep central stromal infiltrates, severe AC reaction with dense sterile hypopyon. Risk factors: Corneal trauma, filtering bleb infection, chronic dacryocystitis Pseudomonas keratitis: Rapid progression, dense stromal infiltrate, marked suppuration, descemetocele formation, corneal perforation, greenish discharge. Risk factors: Soft contact lenses, burns/ immunocompromised patients Fungal keratitis: Dry looking Ulcer with feathery margins with surrounding corneal infiltrates (grayish white) and edema and a dried appearance of surrounding cornea which is clear—fixed hypopyon which is convex upwards and may wax and wane. Satellite lesions and thick endothelial exudates and it may presents with ring infiltrate .

Acanthamoeba keratitis: conjunctival congestion, ring Infiltrates with epithelial defect along with areas of stromal thinning and furrowing and stromal haze. However, diffuse and satellite infiltrates are also common. Acanthamoeba keratitis can be contact lens or non-contact

lens related. Hypopyon is also a common finding in acanthamoeba. Radial keratoneuritis can also be noted and can be identified as a whitish outline of the corneal nerves.

- Non-tuberculous mycobacteria : Classical "Cracked wind-shield appearance" Single or multifocal infiltrates within the interface with no epithelial defect or AC reaction
- Nocardia keratitis : Raised, superficial pinhead-like infiltrates in a wreathlike configuration or brush fire border or cracked windshield appearance
- Infectious crystalline keratopathy : Fine needle-like extensions in the corneal stroma, resembling a snowflake.

8. Investigations

Identification of etiology underlying the disease is important for successful management and it requires laboratory investigations.

- **Microscopic examination**

Examination after scraping of Ulcer and cultures is considered as a gold standard for the definitive diagnosis. Smear and culture for an organism can be prepared by scraping the corneal Ulcer's base and leading-edge or margin using 26 G needle, Kimura spatula or sterile surgical blade no 15 on Bard Parker Handle. Proparacaine hydrochloride 0.5% can be used as an anesthetic. Scrape in one direction. Loose mucus and necrotic tissue should be removed from the surface of the Ulcer prior to scraping. These scrapings are immediately placed on glass slides for light microscopy and agar plates for culture (Blood agar, chocolate agar, Sabouraud's agar). Scraping material can be use for following tests:

- Direct microscopic examination
- Steps for gram staining: Fix smear using either methanol for 5-10 minutes or pass through flame 2-3 times. Flood slide with Crystal Violet and allow for 1 minute and rinse with tap water. Then, flood slide with Gram's Iodine and allow for 1 minute and drain with tap water. Decolorize with decolorize until color stops running from the smear. Now flood slide with Safranin Stain. Allow for 30 sec, rinse with water and allow it to air dry.
- KOH preparation: Spread scrape material thinly with the help of a spatula on a slide. Put one drop of 10% KOH on the scraping. Place a slide cover slip on the slide and examine the slide under a microscope.KOH helps in loosening corneal stromal lamellae and exposes more fungal

filaments. Yeasts appear round budding cells. Aspergillus has septate hyphae with acute angle branching, while rhizopus has septate hyphae with right-angle branching.

- Giemsa Romonowsky stain: eosin, methylene blue, azure dye differentiates bacteria from fungi, cyst and trophozoites of acanthamoeba.
- Acid fast stain :Carbol-fuchsin or Ziehl-Neelsen acid-fast stain for Mycobacteria, Actinomyces or Nocardia.
- Fluorochromatic Stains, Acridine-orange and Calcofluor-white with epifluorescence microscope.
- Modified Grocott-Gomori, Methenamine-Silver Nitrate Stain show fungi and modified for the examination of corneal scrapings.

- **Culture and antibiotic susceptibility testing**

Direct plating on culture media is preferable to transport media. For aerobic culture, it takes around 7days for reporting and for anaerobic cultures it takes around 7 to 14 days. Mycobacterial and fungal cultures are held for 4 to 6 weeks before being reported as no growth. Different media used are given below in the figure.

Antimicrobial Susceptibility

Antimicrobial susceptible testing is performed by

- Kirby Buaer Disk Diffusion method using ciprofloxacin (5 μg), ofloxacin (5 μg), gatifloxacin (5 μg), tobramycin (10 μg), chloramphenicol (30 μg), amikacin (30 μg), gentamicin (10 μg), moxifloxacin (5 μg) as per Clinical and Laboratory Standards Institute Guidelines. Disk diffusion method assesses antibiotic sensitivity of bacteria. It uses antibiotic discs to evaluate the extent to which bacteria are affected by those antibiotics. Antibiotic susceptibility does not necessarily directly reflex clinical susceptibility.
- Microdilution techniques: dilution methods allow the quantitative assessment of the antimicrobial susceptibility by determining the lowest concentration of the agent capable of inhibiting the growth of the tested organism, which is described as the minimum inhibitory concentration (MIC).

3. Corneal biopsy

It can be performed at the slit lamp biomicroscope or operating microscope.

Indications

- Lack of response to treatment
- Repeated negative cultures.
- Infiltrate is located in the mid-deep stroma with overlying uninvolved tissue

After instillation of topical anesthetic, a small trephine or blade is used to excise a small piece of stromal tissue at the edge of the infiltrate, which can be sent for culture as well as histopathology. 3 mm trephine used trephination of both infected and clinically normal 1 mm rim taken for diagnosis.

4. Suture biopsy

It is used for deep corneal abscesses. Short 7–0/8–0 vicryl or silk suture is used. Suture is passed through the depth of the infiltrate and cut into two pieces and sent for bacterial and fungal culture and sensitivity.

5. Confocal Microscopy

With the advancement in technology, direct visualization of pathogens within the patients cornea is possible. It can be used as a Screening tool -Useful when relatively large infecting organisms (15 microns) are present, as are seen in Acanthamoeba, filamentous fungal, and microsporidia. In Vivo confocal microscopy is non invasive technique available in clinical settings. There are presently two modalities available for clinical use: scanning slit IVCM (Confoscan, Nidek Technology, Fremont, CA) and laser scanning IVCM (HRT3 with Rostock corneal module, Heidelberg Engineering, Heidelberg, Germany). Acanthamoeba cyst can be identified as double walled ovoid bodies and fungal bodies were seen as bright linear filamentous structures with bright borders that appear as parallel lines (double walled linear bodies) .It helps us to initiate treatment and monitor the patient. Sensitivity is high, but specificity is low.

6. Histopathology

Histopathological examination may reveal epithelial ulceration, destruction of Bowman's layer and anterior stroma and diffuse infiltration .Fungus appears as hollow, unstained filaments with two parallel borders and Virus as neutrophilic stromal infiltrates while acanthamoeba shows cysts and trophozoites.

TREATMENT

1. Medical management of bacterial keratitis:

Bacterial keratitis must be considered as an ocular emergency due to its rapid progression and complications.

- Empirical antibiotic therapy should be promptly started and there are two treatment options available to choose from, fluoroquinolone monotherapy or a combination therapy of fortified antibiotics (cefazolin 5% and tobramycin or gentamicin 1.4%). Depending on the severity, the frequency of drugs are adjusted but it is usual to start half-hourly drops all through 24 h for most patients. Thereafter, frequency is reduced based on the clinical response. Treatment of suspected cases of microbial keratitis initially with topical fortified antibiotics has long been the gold standard and the role for fluoroquinolone monotherapy continues to be researched, although studies have shown both treatment options to be comparable (4-6). The differences between monotherapy and combination therapy is given in the table (7). Antibiotic coverage and mode of preparation of fortified antibiotics is given below (Figure 2).

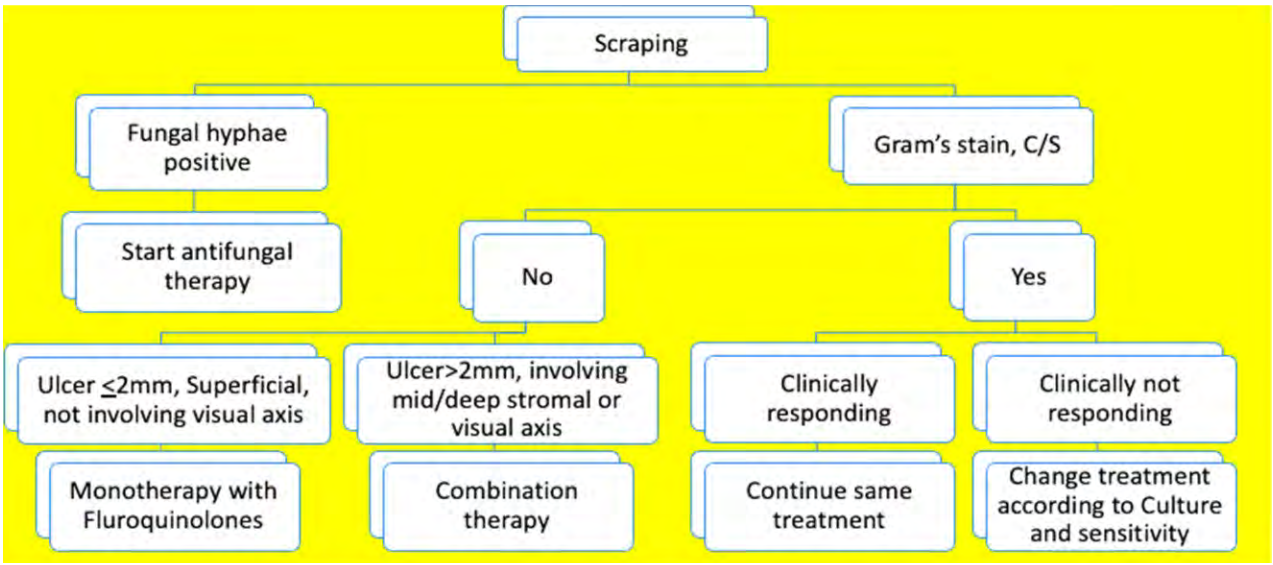

Figure 2: Management of Corneal Ulcer

Monotherapy is advocated

- when ulcer in periphery
- Small (<3mm)

- Drugs which can be used -Fluoroquinolones (Ofloxocin 0.3%, Ciprofloxacin 0.3%, Gatifloxacin 0.3%, Moxifloxacin 0.5%)

Combination therapy

- Covers both gram positive and negative
- Fortified cefazoline 5% with fortified Tobramycin 1.3% or fluoroquinolone with fortified Tobramycin 1.3% is being advocated.

Systemic therapy is indicated when there is

- Systemic involvement – e.g.: culture positive for Neisseria , Haemophilus species.
- Severe corneal thinning with threatened or actual perforation
- Scleral involvement
- Endophthalmitis

2. Supportive therapy

Cycloplegics like homatropine or atropine, anti-inflammatory drugs, antiglaucoma medications and analgesics can be given. Preservative free lubricants can be added in healing phase. Role of corticosteroid in treating the bacterial Ulcer is still controversial. The SCUT treatment study found no benefit of topical corticosteroid therapy using prednisolone sodium phosphate 1% in conjunction with broad spectrum topical antibiotics.

Signs of healing:

- Reduced pain and discharge
- Decreased conjunctival injection
- Consolidation of infiltrate, decrease in size and sharper demarcation margins of infiltrate
- Reduced stromal edema, endothelial plaque
- Re-epithelization
- Vascularization
- Cessation of corneal thinning
- Reduced AC reaction

Medical Management of Fungal Keratitis

Natamycin 5% suspension is the choice for treatment of filamentous fungal keratitis. Surface debridement can be done which helps to remove slough ,reduce load of infection and enhances

the drug penetration. Drops are used every half to one hourly initially which is to be tapered as per the clinical response. Response to treatment in fungal infections takes time and complete resolution often may require up to 4-8 weeks of treatment. Mycotic ulcer treatment trial (MUTT) I compared topical natamycin and voriconazole which revealed that Natamycin had showed significant clinical improvement as compared to voriconazole. MUTT II compared oral voriconazole and placebo which reported benefits of oral voriconazole in treating Fusarium Ulcer. Steroids are contraindicated in fungal ulcers (Figure 3).

Amphotericin B is effective against yeasts particularly but less effective against filamentous fungi and hence it is therefore the first agent of choice against yeasts. Amphotericin B (0.15%) drops can be considered alone or in combination with natamycin in refractory cases; Intracameral 5-10 µg amphotericin B has also been used successfully in patients refractory to topical and oral antifungals (8).

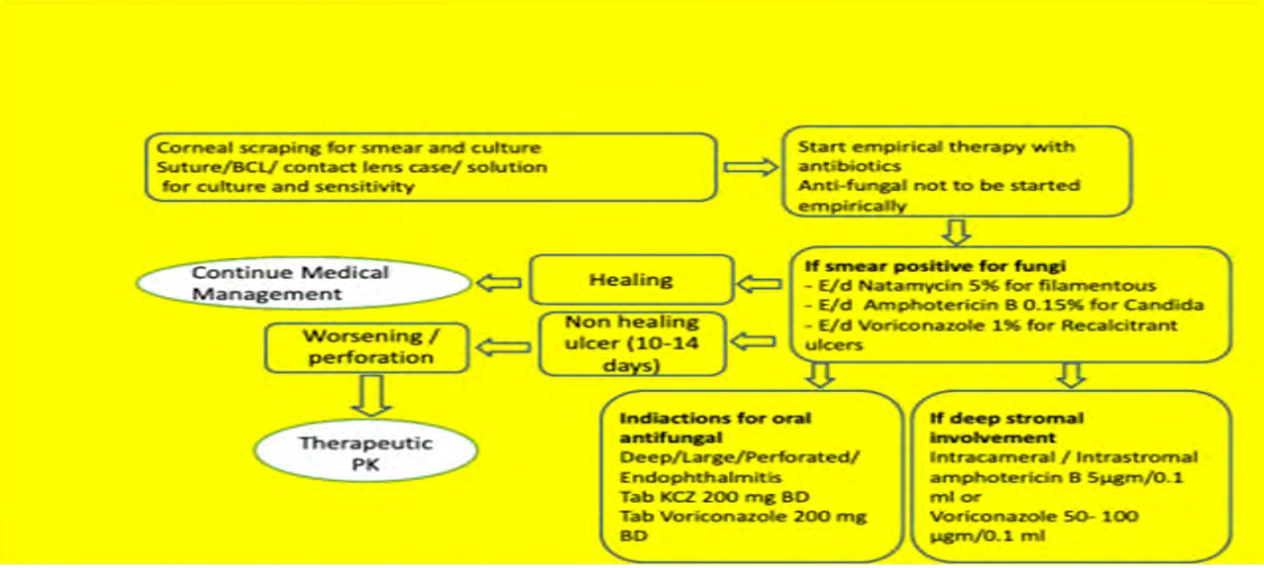

Figure 3: Management of Fungal Corneal Ulcer

Medical Management of Viral Keratitis

A flowchart regarding management of HSV keratitis and classical clinical trials related to viral keratitis is given below (Figure 4).

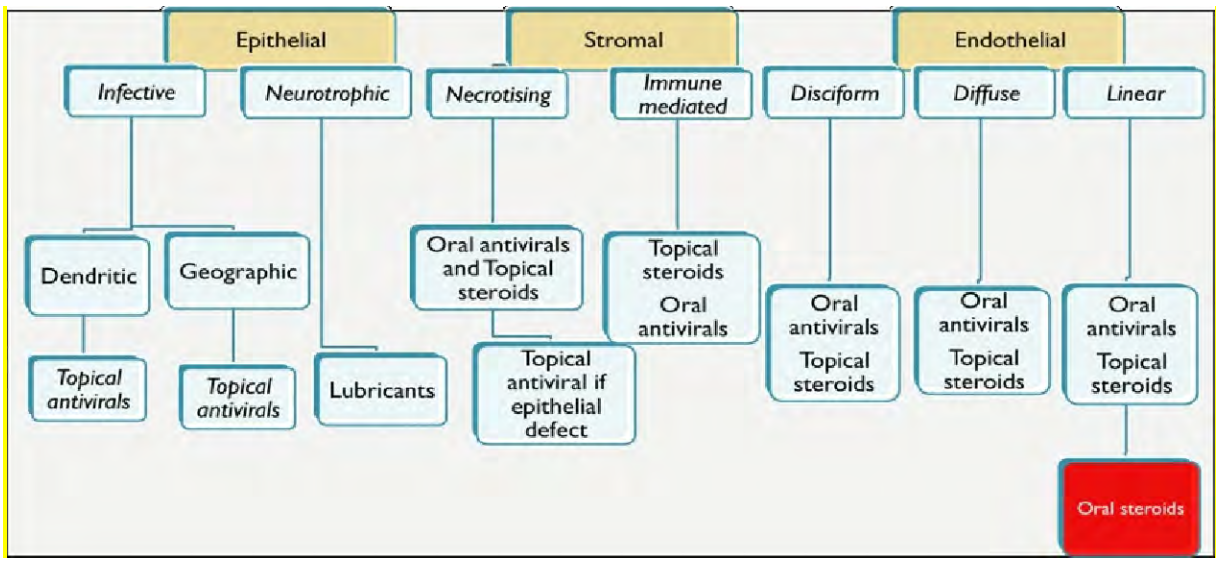

Figure 4: Management of Viral Keratitis (Herpes Simplex)

Herpes Simplex virus keratitis

1. **Epithelial disease without stromal involvement**

Infected epithelial cells are debrided with sterile cotton tipped applicator and acyclovir 3% eye ointment is started five times a day. Antivirals are used for 2-3 weeks. Topical steroids are contraindicated in infectious epithelial disease.

2. **Epithelial trophic ulceration**

Intensive lubrication with preservative-free tear substitutes is usually successful . Antivirals does not have a role. Bandage contact lenses and amniotic membrane grafting can also be tried in refractory cases. In severe cases tarsorrhaphy or a conjunctival flap can be done.

3. **Stromal keratitis**

According to a herpetic eye disease study (HEDS) combination of topical steroids and antivirals reduces the chance of persistence or progression of stromal inflammation and thereby shortens the duration of stromal keratitis.(9) Additional use of oral acyclovir was found to be of no benefit.

4. Trabeculitis and Iridocyclitis

Topical steroid and antiviral combination is usually recommended. HEDS also recommends additional oral acyclovir for iridocyclitis (10).

5. Recurrent ocular disease and oral prophylaxis

The HEDS study proved that oral acyclovir 400 mg twice daily reduces the recurrence of herpetic eye disease(11).

Herpes Zoster

Herpes zoster ophthalmicus (HZO) treated with oral acyclovir 800 mg five times a day for 7-10 days, ideally initiated within 72 h of the onset of symptoms. Famciclovir is more bioavailable when given orally than acyclovir and its active metabolite penciclovir triphosphate has an intracellular half-life nearly ten times that of acyclovir. The recommended dosage is 500 mg/day for seven days. Neurotrophic ulceration is one of the major complications of HZO. Preservative-free lubricants, bandage contact lens, tarsorrhaphy, amniotic membrane grafts, and conjunctival flaps may be required.

CONCLUSION

Corneal Ulcers management poses a major challenge for treating ophthalmologist due to its potential to develop vision threatening complications in a short span of time. Microbial keratitis may lead to severe corneal thinning, perforation, endophthalmitis and dense stromal scarring causing severe visual debilitation. The proper diagnosis and early identification of organism may help in the early resolution of disease and reducing the morbidity.

REFERENCES

1. Whitcher JP, Srinivasan M, Upadhyay MP. Corneal blindness: a global perspective. Bull World Health Organ. 2001 Jan 1;79(3):214–21.

2. Gupta AKR, Gupta RKR. Regional Variation of Epidemiological and Microbiological Profile of Microbial Keratitis In India. Off Sci J Delhi Ophthalmol Soc. 2016 ;10;27(2):151–3.

3. Al-Mujaini A, Al-Kharusi N, Thakral A, Wali U. Bacterial Keratitis: Perspective on Epidemiology, Clinico-Pathogenesis, Diagnosis and Treatment. Sultan Qaboos Univ Med J. 2009 Aug 1;9:184–95.

4. Ofloxacin monotherapy for the primary treatment of microbial keratitis: a double-masked, randomized, controlled trial with conventional dual therapy. The Ofloxacin Study Group. Ophthalmology. 1997 ;104(11):1902–9.

5. Hyndiuk RA, Eiferman RA, Caldwell DR, Rosenwasser GO, Santos CI, Katz HR, et al. Comparison of ciprofloxacin ophthalmic solution 0.3% to fortified tobramycin-cefazolin in treating bacterial corneal ulcers. Ciprofloxacin Bacterial Keratitis Study Group. Ophthalmology. 1996 ;103(11):1854–62; discussion 1862-1863.

6. Panda A, Ahuja R, Sastry SS. Comparison of topical 0.3% ofloxacin with fortified tobramycin plus cefazolin in the treatment of bacterial keratitis. Eye. 1999;13:744–77 -

7. Gokhale NS. Medical management approach to infectious keratitis. Indian J Ophthalmol. 2008 ;56(3):215–20.

8. Kaushik S, Ram J, Brar GS, Jain AK, Chakraborti A, Gupta A. Intracameral amphotericin B: initial experience in severe keratomycosis. Cornea. 2001;20(7):715–9.

9. Barron BA, Gee L, Hauck WW, Kurinij N, Dawson CR, Jones DB, et al. Herpetic Eye Disease Study. A controlled trial of oral acyclovir for herpes simplex stromal keratitis. Ophthalmology. 1994 ;101(12):1871–82.

10. A controlled trial of oral acyclovir for iridocyclitis caused by herpes simplex virus. The Herpetic Eye Disease Study Group. Arch Ophthalmol Chic Ill 1960. 1996;114(9):1065–72.

11. Acyclovir for the prevention of recurrent herpes simplex virus eye disease. Herpetic Eye Disease Study Group. N Engl J Med. 1998;339(5):300–6.

REVIEW ARTICLE

Review of Drugs and Therapy for the Management of Neovascular Age-Related Macular Degeneration

Dr. Seema Meena, Dr. Achala Rawat, Dr. Kavita Bhatnagar,
Dr. Nikhil Agrawal, Dr. Kriti Jai Singh, Dr. Manjari Tandon
Department of Ophthalmology, AIIMS, Jodhpur, Rajasthan
E-mail: nikhil.aiims87@gmail.com

ABSTRACT

Age related macular degeneration is the leading cause of irreversible blindness in elderly patient in western world and neovasualar ARMD constitute 10 percent of all cases. Anti-VEGF form the main stay of treatment in the present times but their use is restricted by financial impact patients compliance. Therefore, numerous drugs and therapy are under trial to search the ideal treatment. This review aims to review the current treatment options and new therapies in pipeline which include bio-similar alternatives, new anti-VEGF intravitreal agents, and gene therapy.

INTRODUCTION

Age-related macular degeneration (ARMD) is the leading cause of visual disability worldwide, with incidence ranging from 9-25% at ages 65-75 years [1]. In the western world, advanced forms of age-related macular degeneration (ARMD) are the most common cause of irreversible vision loss in patients 65 years or older, with rising to 288 million cases worldwide. **[2,3]**

There are two main types of ARMD: dry, comprising 90% of cases, and wet (exudative, neovascular type). Neovascular AMD is less common, affecting only 10% of AMD patients. However, it is more likely to lead to significant visual loss. [4] This type of AMD is characterized by the growth of pathologic choroidal neovascularization (CNV) beneath the macula, which causes exudation of blood and fluid into the macula caused by cytokine vascular endothelial growth factor-A (VEGF-A). [5]

The VEGF Inhibitors forms the mainstay of treatment for wet ARMD, improving visual acuity, central macular thickness and pigment epithelial detachment (PED) [6]. While many trials have shown beneficial results with anti-VEGF medications, there are limitations to their use. Earlier studies have shown that 20% of patients lose their vision despite the best treatment.[7]

This review aims to review the current treatment options and new therapies in pipeline which include bio-similar alternatives, new intravitreal agents, and gene therapy.

PREVIOUSLY ESTABLISHED TREATMENTS

Numerous treatment modalities were available prior to anti-VEGF therapy including focal laser treatment, intravitreal steroids, verteporfin photodynamic therapy (PDT), submacular CNV surgical extraction, retinal translocation, radiation and other medications. Unfortunately, most of these treatment strategies did not significantly improve vision, and many patients permanently lost vision. The therapies are still available but infrequently used today for the treatment of wet AMD. Verteporfin PDT is still commonly used to treat polypoidal choroidopathy, a variant of macular degeneration, but infrequently used for the treatment of wet AMD. [8]

Laser Photocoagulation

It works on the principle of cauterizing the feeder vessels of sub-foveal choroidal neovascularization, thus preventing the disease's subretinal fluid accumulation and progression.[9]The macular photocoagulation study showed severe visual loss in 25% of patients of the laser photocoagulation group compared to 60 % in the observation group. [9] However, the occurrence of recurrent and persistent choroidal neovascularization after laser photocoagulation decreases this treatment method's effectiveness. [9]

Photodynamic Therapy

Photodynamic therapy (PDT) with verteporfin effectively decreased the chances of moderate and severe vision loss in subfoveal CNV. Still, vision loss continues in the first year of treatment and to a lesser extent during the second and third years. [10]

Submacular CNV Surgical Extraction

The studies had reported the effect of surgical removal of the neovascular net with or without transplantation of RPE or iris pigment epithelium cells. However, the results were very unsatisfactory with few patients experiencing improvement in visual acuity. The removal of RPE cells in submacular surgery appears to limit the final visual outcome, making this type of surgery ineffective in subfoveal CNVM in ARMD.[11,12]

Macular Translocation

Macular rotation or translocation surgery is technically a more complex surgical procedure and may fail if there is insufficient translocation, development of cystoid macular edema or recurrence of the CNVM.[13,14]

PRESENT MODALITIES OF TREATMENT

In the present times, Intravitreal anti-vascular epithelial growth factor (VEGF) agents like Bevasizumab, Ranibizumab, Aflibercept are the mainstay of treatment. Recently, the FDA has approved fourth intravitreal drug, Brolucizumab in the last quarter of 2019.

***Pegaptanib**:*

Pegaptanib is a selective anti-vascular endothelial growth factor aptamer that acts in the extracellular space to inhibit VEGF165. Aptamers are oligonucleic acid or peptide molecules that bind a specific target molecule. Pegaptanib was approved by the food and drug administration (FDA) to treat neovascular ARMD in 2004. Clinical trials like VISION have demonstrated clinical benefit in the treatment of NV-AMD and that better results may occur if lesions are treated early in the disease process (15- 17). However, due to the availability of more effective treatments, the use of this medication has been reduced.

Bevacizumab:

Bevacizumab (Avastin; Genentech), is a full-length humanized monoclonal antibody that binds to and blocks the action of all VEGF isoforms. Numerous retrospective and prospective studies of intravitreal bevacizumab have reported its efficacy for neovascular AMD and low rates of treatment-related complications. [17-20]

Ranibizumab:

Ranibizumab (Lucentis; Genentech) is a humanized antibody fragment that binds all isoforms of VEGF-A and its related degradation products and is Food and Drug Administration (FDA) approved for the treatment of all subfoveal classic choroidal neovascularization (CNV) subtypes secondary to AMD. The pivotal phase III minimally classic/occult trial of the anti VEGF antibody ranibizumab in the treatment of neovascular AMD (MARINA) and the anti-VEGF antibody for the treatment of predominantly classic choroidal neovascularization (CNV) in AMD (ANCHOR) trial [58-60] demonstrated best-corrected visual acuity (BCVA) outcomes far superior to any previously published study in the treatment of this disease.[21-22]

Aflibercept:

Aflibercept (VEGF Trap-Eye, Eylea, Regeneron Pharmaceuticals) is a new anti-VEGF agent potent VEGF-A and placental growth factor (PlGF), both of which have been shown to be involved in the pathogenesis of neovascular AMD. Randomised clinical trials (VIEW 1 and VIEW 2) had established the efficacy and safety of neovascular AMD treatment. The two studies showed that IVT Aflibercept given every two months after three consecutive monthly injections is equivalent in efficacy and safety to monthly Ranibizumab. [23,24]

Brolucizumab:

Brolucizumab (Beovu; Novartis) was approved in 2019. It is a single-chain antibody fragment, which also targets VEGF-A**.** HAWK and HARRIER trials compared the safety and efficacy of Brolucizumab and aflibercept in Phase 3 trials. In HAWK, patients were randomized to intravitreal Brolucizumab 3 mg, Brolucizumab 6 mg, or aflibercept 2 mg. HARRIER randomized patients to Brolucizumab 6 mg or aflibercept 2 mg. Brolucizumab was non-inferior to Aflibercept in the primary outcomes in both studies.[25]

EMERGING NEO-VASCULAR AMD THERAPIES

Biosimilars

In order to decrease the financial burden of intra-vitreal injections, pharmaceutical companies have attempted to create biosimilar medications as a cheaper alternative. The biosimilar

medications (Table 1 and Table 2) are not exactly the same as generic medications. They replicate only the therapeutic endpoints of existing medications rather than copy their molecular structure. (26-35)

Ranibizumab biosimilars

Razumab, a humanized, monoclonal IgG antibody fragment, is the only biosimilar approved in any country for ranibizumab. It is only available in India and was approved in 2015.

Aflibercept biosimilars:-

Currently, there are no medications approved and released as an aflibercept biosimilar.

FYB203: (Formycon AG, and Bioeq Gmbh) The development of FYB203 (Formycon and Bioeq) is currently underway, and the product is expected to be available in the United States in 2023.

Bevacizumab biosimilars:

OSN-510: A phase 3 randomized clinical trial is underway studying ONS-510 (Outlook Therapeutics) to evaluate the biosimilar against bevacizumab. However, since bevacizumab is already a cost-effective, generally trusted off-label treatment option in the United States, it may be difficult to convince clinicians to opt for a biosimilar instead.

Table 1: Emerging modalities of treatment and their mechanism of action

Drugs and therapy in pipeline	Mechanism of action	Trials
Anti-VEGFs		
Abicipar peg	Ankyrin Repeat protein binds to VEGF-A	CEDAR ,SEQUIA
OPT-302	VEGF fusion protein targets VEGDC VEGF D	
Conbercept	Recombinant human fusion protein	PANDA 1, PANDA 2
KSI-301	ANTI VEGF ANTIBODY	Dazzle

Drugs and therapy in pipeline	Mechanism of action	Trials
Combination of VEGF and anti platelet derived growth factor		
CLS-AX (Ataxanib)	Tyrosine kinase inhibitor	Injected in suprachoroidal space
Pegleranib (Fovista)	Pegylated DNA apter binds to PDGF	
Rinucumab (Regeneron)	Anti PDGF receptor b antibody	Capella
DE-120	Dual tyrosine kinase inhibitor	
X-82	oral PDGF and VEGF A inhibitor	Apex
Combination of VEGF and tissue factor therapies		
ICON 1	Factor 8A linked with Fc portion of IGG 1	EMERGE trial
Combination of VEGF and Tie 2 Receptors therapies		
Faricimab	Biospecific antibody targets VEGF A and Angiopoietin 2	AVENUE, STAIRWAY, LUCRENE, TENAYA
REGN 910	Inhibits Angiopoeitn 2	ONYX
ARP-1536	Monoclonal Antibody activates Tie @ receptor	

Table 2: Bio-similars and their status

S.No.	Mechanism	Brand name	Status
1.	Ranibizumab biosimilars	Razumab	Approved
		FYB201	Completed Phase III trial
		SB-11	Completed Phase III trial
		Xlucane	Underway Phase III trial
		PF582	Completed Phase I/II trial
		CHS3551	Preclinical trial
2.	Aflibercept biosimilars	FYB203	Preclinical trial
		ALT-L9	In phase I trial
		MYL1710	Underway Phase III trial
		CHS-2020	Preclinical trial
3.	Bevacizumab biosimilars	ONS-5010	Completed Phase III trial

Emerging VEGF targets

Abicipar Pegol:

Abicipar pegol is an anti-VEGF molecule based on the ankyrin repeat proteins (DARPin) family that binds to VEGF-A. CEDAR and SEQUOIA tested the effectiveness of Abicipar Pegol versus Ranibizumab in the treatment of nAMD patients. Results showed that Abicipar is the only anti-VEGF that has maintained stable vision in >91% of patients on a fixed 12-week regimen. (76) However, similar to Brolucizumab, Abicipar has demonstrated high rates of intraocular inflammation, 15.4%, as compared to 0.3% with ranibizumab in phase III trials. The drug is currently being reviewed for regulatory application by the FDA, with expected action coming in mid-2020. [36,37]

Conbercept:

Conbercept (Lumitin) is a recombinant human fusion protein of extracellular domains of VEGFR1, VEGFR2 and the portion of Fc IgG1. Multicentric Randomised Controlled trial PANDA-1 and PANDA-2 are the ongoing trial comparing the efficacy of Coebrnacept as compared to Aflibercept. The studies are fully enrolled, with results expected in 2021.[38]

Emerging combination VEGF and anti-platelet derived growth factor (PDGF) therapies:

There has been a concerted effort in producing medications that target both the anti-VEGF and anti-PDGF pathways to enhance medication response.[39–40]

Pegpleranib:

Pegpleranib (Fovista) is a 32 pegylated DNA aptamer that selectively binds to PDGF-BB homodimers and PDGF-AB heterodimers to prevent their binding with PDGF tyrosine-kinase receptors expressed on pericytes. (40-41)

Rinucumab:

Rinucumab (Regeneron) is an anti-PDGF receptor-β antibody. It has been co-formulated with Aflibercept for a single injection that was studied in the phase 2 CAPELLA trial [41]

Emerging combination of VEGF and tissue factor therapies:

Tissue factor is related to the production of Choroidal neovascular membrane in neovascular AMD. So targeting the tissue factor may improve visual outcomes.[42]

ICON-1:

ICON-1 (Iconic Therapeutics, San Francisco, California) is a combination product of factor VIIIa linked with the Fc portion of human IgG1. Investigation of ICON-1 has been undertaken with EMERGE, a phase II, randomized, double-masked study in 88 patients with CNV in neovascular AMD.[43]

Emerging combination of VEGF and Tie2 receptor therapies:

Activation of the Tie-2 receptor stabilizes vasculature and limits permeability. Consequently, modulating the Tie-2 receptor in combination with anti-VEGF-A therapy may provide enhanced efficacy over anti-VEGF-A monotherapy.[42-44]

Faricimab:

Faricimab (Roche/Genentech) is a biospecific antibody targeting VEGF-A and angiopoietin-2. AVENUE was a Phase II, multiple-centre, randomized, double-masked, active comparator-controlled trial of intravitreal Faricimab on treatment of neovascular ARMD patients. AVENUE concluded efficacy and safety of Faricimab Q4w and Q8w compared with monthly doses of ranibizumab.[44-45].

Sustained treatments:

Ranibizumab port delivery system (PDS):

The port delivery system (PDS), manufactured by Genentech (South San Francisco, CA), is a permanent and refillable drug delivery system surgically inserted into the patient's eye through a self-sealing implant in the sclera and pars plana. The reservoir in the implant allows for drug replenishment in the clinic without removing it from the eye. Ranibizumab in the PDS moves by passive diffusion down a concentration gradient from the implant into the vitreous. (46-47)

This PDS system has shown promising results in the trials LADDER and ARCHWAY.

LADDER, a phase II trial, showed comparable visual outcomes in patients treated with the 100 mg/ml treatment arm and the monthly injection arm. (99) ARCHWAY, a phase III trial, utilized the 100 mg/ml surgical implant and showed non-inferior outcomes and equivalent visual acuity compared to monthly ranibizumab injections. [46,47]

Sunitinib maleate, GB-102 (GrayBug Vision), OTX-TKI (Ocular Therapeutix), The Durasert Bioerodible TKI (EyePoint Pharmaceuticals), ENV1305 (Envisia Therapeutics) are other port delivery systems that are under the trail. (47)

NT503 encapsulated cell therapy (ECT) implant:

NT-503 is a novel VEGF-A receptor fusion protein that is continuously secreted by the platform. A Neurotech press release announced that the phase II study was discontinued due to a more

significant than expected number of participants requiring rescue medication in the treatment arm. (48)

Gene therapy

Gene therapy in the future may provide a promising alternative compared to other modalities as the capsid enable the translation of Viral genetic material in to protein which can modify the pathogenesis of neovascular AMD.[49,50.51]

Topical Treatments

Pazopanib (GlaxoSmithKline) is a topical formulation of a tyrosine kinase inhibitor, which inhibits both VEGF-A and PDGF. The drop has been evaluated in a few trials for its efficacy in treating wet AMD. In studies, it does not show significant improvement in choroidal neovascular membrane size or characteristics of imaging, or in baseline retinal thickness or morphology. Therefore further development was halted. However other topical agents are under trial. [52-54]

CONCLUSION

The use of Anti-VEGF has brought significant improvement in the management of wet ARMD. However the complex pathogenesis of the disease , financial impact and patient compliance are the limitations of current treatment options. Therefore it's the need of the hour to channelize resources toward development of gene therapy, topical drops or long term depot drugs which may enhance compliance and cost without affecting its efficacy.

REFERENCES

1. Prokofyeva E, Zrenner E. Epidemiology of major eye diseases leading to blindness in Europe: a literature review. Ophthalmic Res 2012;47(4):171-88

2. Wong WL, Su X, Li X, et al. Global prevalence of age-related macular degeneration and disease burden projection for 2020 and 2040: a systematic review and meta-analysis. Lancet Glob Health. 2014;2: e106–16.

3. A. M. Joussen and N. Bornfeld, “The treatment of wet age related macular degeneration,” Deutsches Arzteblatt, vol. 106, no. 18, pp. 312–317, 2009.

4. Al-Latayfeh M, Silva PS, Sun JK, et al. Antiangiogenic therapy for ischemic retinopathies. Cold Spring Harb Perspect Med 2012;2(6):a006411

5. Moutray T, Chakravarthy U. Age-related macular degeneration: current treatment and future options. Ther Adv Chronic Dis 2011;2(5):325-31

6. Martin DF, Maguire MG, Ying GS, et al. CATT Research Group. Ranibizumab and bevacizumab for neovascular age-related macular degeneration. N Engl J Med 2011;64(20):1897-908

7. Chakravarthy U, Harding SP, Rogers CA, et al. IVAN study investigators. Alternative treatments to inhibit VEGF in age-related choroidal neovascularization: 2-year findings of the IVAN randomised controlled trial. Lancet 2013;382(9900):1258-67

8. Joussen AM, Bornfeld N. The treatment of wet age-related macular degeneration. Dtsch Arztebl Int 2009;106:312-17

9. B. S. Hawkins, "Laser photocoagulation of subfoveal recurrent neovascular lesions in age-related macular degeneration: results of a randomized clinical trial," Archives of Ophthalmology, vol.109, no. 9, pp. 1232–1241, 1991.

10. Blumenkranz MS, Bressler NM, Bressler SB, et al; Treatment of Age-Related Macular Degeneration With Photodynamic Therapy (TAP) Study Group. Verteporfin therapy for subfoveal choroidal neovascularization in age-related macular degeneration. Arch Ophthalmol. 2002;120(10):1307-1314.

11. Algvere PV, Berglin L, Gouras P, Sheng Y. Transplantation of fetal retinal pigment epithelium in age-related macular degeneration with subfoveal neovascularization. Graefes Arch Clin Exp Ophthalmol 1994;232:707-16.

12. Thomas MA, Dickinson JD, Melberg NS, et al. Visual results after surgical removal of subfoveal choroidal neovascular membranes. Ophthalmology 1994;101:1384-96.

13. Scheider A, Gundisch O, Kampik A. Surgical extraction of subfoveal choroidal new vessels and submacular haemorrhage in age-related macular degeneration: results of a prospective study. Graefes Arch Clin Exp Ophthalmol 1999;237:10-5.

14. Pieramici DJ, Juan ED, Fujii GY, et al. Limited inferior macular translocation for the treatment of subfoveal choroidal neovascularization secondary to age-related macular degeneration. Am J Ophthalmol 2000;130:419-28.

15. Gragoudas, E.S., Adamis, A.P., Cunningham, E.T., Feinsod, M. , Guyer, D.R. Pegaptanib for neovascular age-related macular degeneration. N Engl J Med. 2004; 351(27): 2805–16.

16. Chakravarthy, U., Adamis, A.P., Cunningham, E.T. . Year 2 efficacy results of 2 randomized controlled clinical trials of Pegaptanib for neovascular age-related macular degeneration. Ophthalmology. 2006; 113(9): 1508. e1–25

17. Spaide RF, Laud K, Fine HF, et al. Intravitreal bevacizumab treatment of choroidal neovascularization secondary to age-related macular degeneration. Retina 2006; 26:383–390.

18. Emerson MV, Lauer AK, Flaxel CJ, et al. Intravitreal bevacizumab (Avastin) treatment of neovascular age-related macular degeneration. Retina 2007; 27:439–444.

19. Pedersen R, Soliman W, Lund-Andersen H, Larsen M. Treatment of choroidal neovascularization using intravitreal bevacizumab. Acta Ophthalmol Scand 2007; 85:526–533.

20. Aggio FB, Farah ME, Silva WC, Melo GB. Intravitreal bevacizumab for exudative age-related macular degeneration after multiple treatments. Graefes Arch Clin Exp Ophthalmol 2007; 245:215–220.

21. Brown DM, Kaiser PK, Michels M, et al. Ranibizumab versus verteporfin for neovascular age-related macular degeneration. N Engl J Med 2006; 355:1432–1444.

22. Brown DM, Michels M, Kaiser PK, et al. Ranibizumab versus verteporfin photodynamic therapy for neovascular age-related macular degeneration: two-year results of the ANCHOR study. Ophthalmology 2009; 116:57–65; e5.

23. Rosenfeld PJ, Brown DM, Heier JS, et al. Ranibizumab for neovascular age related macular degeneration. N Engl J Med 2006; 355:1419–1431.

24. J. S. Heier, D. M. Brown, V. Chong et al., Intravitreal aflibercept (VEGF trap-eye) in wet age-related macular degeneration. Ophthalmology, vol. 119, no. 12, pp. 2537–2548, 2012.

25. Dugel, P.U.; Koh, A.; Ogura, Y.; Jaffe, G.J.; Schmidt-Erfurth, U.; Brown, D.M.; Gomes, A.V.; Warburton, J.; Weichselberger, A.; Holz, F.G. HAWK and HARRIER: Phase 3, Multicenter, Randomized, Double-Masked Trials of Brolucizumab for Neovascular Age-Related Macular Degeneration. Ophthalmology 2020, 127, 72–8

26. Sharma A, Kumar N, Kuppermann BD, Bandello F, Loewenstein A. Understanding biosimilars and its regulatory aspects across the globe: an ophthalmology perspective. Br J Ophthalmol. 2020;104:2–7.

27. Sharma A, Reddy P, Kuppermann BD, Bandello F, Lowenstein A. Biosimilars in ophthalmology: "Is there a big change on the horizon?" Clin Ophthalmol. 2018;12:2137–43.

28. Holz FG, Oleksy P, Ricci F, Kaiser PK, Kiefer J, Schmitz-Valckenberg S; COLUMBUS-AMD Study Group. Efficacy and Safety of Biosimilar FYB201 Compared with Ranibizumab in Neovascular Age-Related Macular Degeneration. Ophthalmology. 2021 May 3:S0161-6420(21) 00325-0. doi: 10.1016/j.ophtha.2021.04.031.

29. Sharma A, Reddy P, Kuppermann BD, Bandello F, Lowenstein A. Biosimilars in ophthalmology: "is there a big change on the horizon?" Clin Ophthalmol. 2018;12:2137-2143.

30. Woo SJ, Veith M, Hamouz J, et al. Efficacy and Safety of a Proposed Ranibizumab Biosimilar Product vs a Reference Ranibizumab Product for Patients with Neovascular Age-Related Macular Degeneration: A Randomized Clinical Trial. JAMA Ophthalmol. 2021;139(1):68–76.doi:10.1001/jamaophthalmol.2020.5053

31. Comparing the efficacy and safety of biosimilar candidate xlucane versus lucentis® in patients with nAMD (XPLORE). ClinicalTrials.gov Identifier: NCT03805100. https://clinicaltrials.gov/ct2/show/NCT03 805100. Accessed 1 Jan 2020.

32. Pfenex to regain full rights to PF582 and announces phase 1/2 results 2019. https://www.prnewswire.com/news-releases/pfenex-to-regainfull-rights-to-pf582-and-announces-phase-12-results-300310159.html. Accessed 1 Jan 2020.

33. Coherus Biosciences. Addressing important unmet needs. Available at: https://www.coherus.com/products-and-pipeline/ . Accessed February 14, 2020.

34. Bioeq. FYB203. 2018. Accessed January 1, 2020. Available at: https://www.bioeq.com/development-programs/fyb203

35. Biosimilar Development. Alteogen Inc. gets IND approval for a clinical study in Korea for Eylea biosimilar (ALT-L9). Available at: https://www.biosimilardevelopment.com/doc/alteogen-inc-gets-ind-approval-for-a-clinical-study-in-korea-for-eylea-biosimilar-alt-l-0001 .

36. A Safety and Efficacy Study of Abicipar Pegol in Patients With Neovascular Age-related Macular Degeneration (CDER). Available at: https://clinicaltrials.gov/ct2/show/NCT02462928. Published 2015.

37. Safety and efficacy of abicipar pegol in patients with neovascular age related macular degeneration; 2015, https://clinicaltrials.gov/ct2/show/ NCT02462486

38. Efficacy and safety trial of conbercept intravitreal injection for neovascular age-related macular degeneration (PANDA-1). 2020. https://clini caltrials.gov/ct2/show/NCT03577899

39. Jaffe GJ, Ciulla TA, Ciardella AP, et al. Dual Antagonism of PDGF and VEGF in neovascular age-related macular degeneration: A phase IIb, multicenter, randomized controlled trial. Ophthalmology. 2017 Feb;124(2):224–234

40. Dunn EN, Hariprasad SM, Sheth VS. An overview of the Fovista and rinucumab trials and the fate of anti-PDGF medications. Ophthalmic Surg Lasers Imaging Retina. 2017 Feb 01;48(2):100–104

41. Regeneron announces phase 2 study of aflibercept co-formulated with rinucumab (anti-PDGFR-beta) shows no benefit over aflibercept alone in neovascular age-related macular degeneration; 2016

42. Jackson TL, Boyer D, Brown DM, et al. Oral tyrosine kinase inhibitor for neovascular age-related macular degeneration: A phase 1 dose-escalation study. JAMA Ophthalmol. 2017 Jun 01;135:761

43. Gonzales CR, Burian G. A phase 2 study (EMERGE) evaluating repeated intravitreal administration of ICON-1 in patients with choroidal neovascularization (CNV) secondary to age-related macular degeneration (AMD). Invest Ophthalmol Vis Sci. 2017;58:37

44. A proof-of-concept study of Faricimab (RO6867461) in participants with choroidal neovascularization (CNV) secondary to age-related macular degeneration (AMD) - FULL TEXT VIEW ClinicalTrials.gov. Clinicaltrials.gov; 2020, https://clinicaltrials.gov/ct2/show/NCT 02484690

45. A study to evaluate the efficacy and safety of faricimab in participants with neovascular age-related macular degeneration (TENAYA). https://clinicaltrials.gov/ct2/show/NCT03823287.

46. Campochiaro PA, Marcus DM, Awh CC, et al. The port delivery system with ranibizumab for neovascular age-related macular degeneration: results from the randomized phase 2 ladder clinical trial. Ophthalmology. 2019;126:1141–5

47. Campochiaro PA, Marcus DM, Awh CC, et al. The port delivery system with ranibizumab for neovascular age-related macular degeneration: results from the randomized phase 2 ladder clinical trial. Ophthalmology.2019;126:1141–1154.

48. NT-503 ECT. [cited 2019 Mar 25]. Available from: http://www.neurotechusa.com/nc-503-ect.htm

49. An equine infectious anemia virus-based gene therapy, RetinoStat(®), for age-related macular degeneration. Hum Gene Ther. 2012;23:980–91.

50. Campochiaro PA, Lauer AK, Sohn EH, et al. Lentiviral vector gene trans- fer of endostatin/angiostatin for macular degeneration (GEM) study. Hum Gene Ther. 2017;28:99–111.

51. Cashman SM, Ramo K, Kumar-Singh R. A non membrane-targeted human soluble CD59 attenuates choroidal neovascularization in a model of age related macular degeneration. PLoS ONE. 2011;6:e19078.

52. Chaney P. Once-daily topical anti-VEGF eye drop for wet AMD and other neovascular eye disease. Ophthalmology Innovation Summit. 96. Danis R, McLaughlin MM, Tolentino M, et al. Pazopanib eye drops: a randomised trial in neovascular age-related macular degeneration. Br J Ophthalmol. 2014;98:172–8.

53. Csaky KG, Dugel PU, Pierce AJ, et al. Clinical evaluation of pazopanib eye drops versus ranibizumab intravitreal injections in subjects with neovascular age-related macular degeneration. Ophthalmology. 2015;122:579–88.

54. Squalamine eye drop fails in wet AMD. No benefit seen when combined with Lucentis. 2018. https://www.retinalphysician.com/issues/ 2018/january-2018/Squalamine-eye-drop-fails-in-wet- amd

Retinopathy Of Prematurity Screening: Our Experience

Dr. Rakesh Porwal, Dr. Ridhima Sharma
Department of Ophthalmology
J.L.N. Medical College & Hospital, Ajmer, Rajasthan
E-mail:dr.rakeshporwal@gmail.com

INTRODUCTION

Retinopathy of prematurity (ROP) is a potentially blinding condition mainly affecting the preterm infants which is characterized by abnormal vascular growth over the immature retina.[1-5] ROP is a dynamic, time-bound disease that is not present at birth. In addition to preterm birth, exposure to excessive oxygen is major risk factor for sight – threatening (ST-ROP). Other risk factors include sepsis, intra-ventricular hemorrhage, respiratory distress, failure to gain weight and blood transfusions, while breast feeding and kangaroo mother care reduce the risk of STROP. Early detection of ST-ROP, followed by urgent laser treatment, is highly effective in preserving the sight of the babies.

In India the menace of retinopathy of prematurity (ROP) blindness had reached alarming proportions. The number of preterm babies born had crossed 3.5 million annually, more than any other nation in the world. Improved neonatal survival, mushrooming of over 700 "special neonatal care units (SNCUs)" in nearly all district headquarters, a very low prevalence of ROP screening programs and only a handful of "ROP specialists" are some of the myriad reasons the country was facing the epidemic of the disease.

With over 20,000 ophthalmologist members of the All India Ophthalmological Society, nearly 2000 Vitreo-Retinal Society of India members, it appears that less than 1% of ophthalmologists

in the country are involved directly in ROP care. There is a need for every NICU and SNCU to have an effective screening strategy, with qualified ophthalmologist or trained pediatrician to have a weekly screening program. This can be accomplished by training more personnel in Indirect Ophthalmoscopy. The challenge can also be met with the use of Telemedicine. A health worker can take a photograph of the retina with RetCam, a digital fiber optic wide-angle fundus camera with a 130-degree view and then transmit it digitally to an eye specialist in a remote area using telemedicine and then the doctor can give a verdict whether the child needs treatment or not. It is imperative to integrate ROP services with newborn and child health services to ensure healthy survival of preterm infants.

The purpose of this study is to report the incidence of ROP and its association with other risk factors by screening the babies at risk of ROP.

PATIENTS AND METHODS

A retrospective review of all the records of ROP screening program in our institution, which include 100 infants who underwent evaluation at Department of Ophthalmology, J.L.N. Medical College & Hospital, Ajmer between February 2021 and September 2021. The patients are referred to us from our hospital and other regions of the district, this is because some of the regions don´t have a proper screening program (personnel or training) that could reach all pre-term infants.

All Infants were screened under supervision of a Pediatrician. Tropicamide 0.5% was used to dilate pupils. One drop of tropicamide was instilled every 10-15 minutes for 4 times starting 1 hour before the scheduled time for examination. Screening of ROP involved indirect ophthalmoscopy using 20 D lens by experienced Ophthalmologist. After instilling proparacaine, a topical anesthetic drop, a wire speculum was inserted to keep the eye-lids apart. First the anterior segment of the eye was examined to look for pupillary dilation, and lens/media clarity; followed by the posterior pole to look for plus disease; followed by sequential examination of all clock hours of the peripheral retina using pediatric scleral indenter. Antibiotic eye drop was instilled in both eyes after examination. The examinations were kept as short as possible and precautions were taken to ensure that emergency situations can be dealt with promptly and

effectively. Discomfort to the baby was minimized by using topical proparacaine before examination and swaddling the baby. Proper sanitation and asepsis was maintained using gloves and mask during examination. First screening examination was carried out at 31 weeks of gestation or 4 weeks of age, whichever was later. Follow-up examinations were conducted until ROP resolution or retinal maturation was achieved and babies with treatable ROP were referred to higher centre for further management.

Inclusion criteria:

• Infants born with gestational age ≤32 weeks

• Infants born with the birth weight ≤2000 gm.

• Selected preterm infants with a gestational age of more than 32 weeks with sickness like need of cardio respiratory support, prolonged oxygen therapy, apnea of prematurity, anemia needing blood transfusion and neonatal sepsis or believed by their attending pediatrician or neonatologist to be at high risk.

Exclusion criteria:

• Clinically unstable and critical newborns.

• Infants whose parents didn't give consent for screening.

International classification of ROP (ICROP) is used for classifying ROP. ROP is categorized based on the severity of the disease into stages (0-5), location of the disease into 3 zones (Zone 1-3), extent of the disease based on clock hours (1-12) and the presence of plus disease.

The retina is divided into three concentric circles, each centered on the optic disc. The retinal vessels grow out from the optic disc to the periphery and the designation of zones corresponds to the vascular developmental pattern.

Zone1: Defined by a circle whose radius is twice the distance from the centre of the optic disc to the centre of macula (Fovea).

Zone 2: Defined by a circle whose radius is the distance from the centre of the optic disc to the nasal margin of the retina (ora serrata).

Zone3: The remainder of the retina. This is crescent-shaped zone that largely involves temporal retina.

ROP Extent:

disease extent is recorded as clock hours 1-12 hours or as twelve 30° sectors or 360°

The clock hours recorded is the total clock hours involved, not just the contiguous sectors.

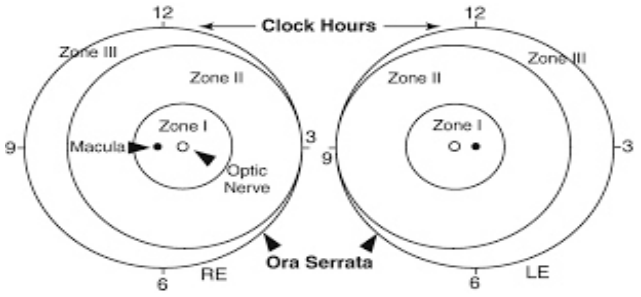

Vascularization of the retina is incomplete or immature prior to the development of ROP.

Disease severity is determined by staging. more than one stage may be present in the same eye.

Stage 1 – Demarcation Line - a thin but definite structure separating the avascular retina anteriorly from the posteriorly vascularized retina.

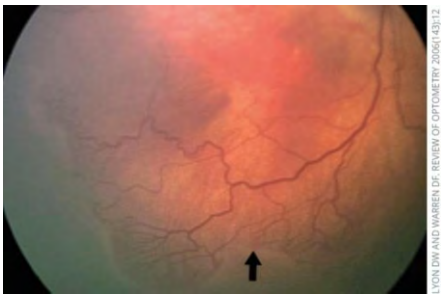

Stage 2 – Ridge - a ridge arising from the demarcation line which has 3 dimensions (height and width) and extends above the retina.

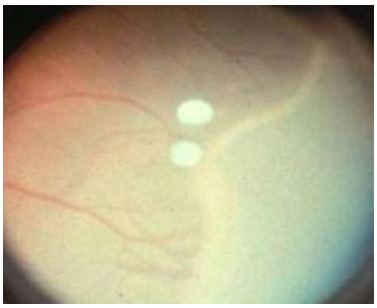

Stage 3 –Extra Retinal Fibro Vascular Proliferation- extra retinal fibro vascular proliferation or neovascularization extends into the vitreous from the ridge.

The posterior aspect of the ridge appears irregular as the proliferation becomes more extensive.

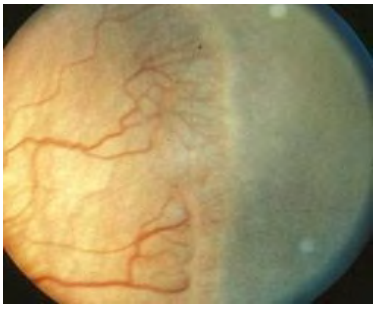

Stage 4 –Partial Retinal Detachment

4a – Extra Foveal Retinal Detachment

4b – Foveal Retinal Detachment

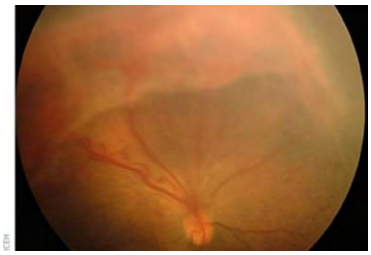

Stage 5 –Total Retinal Detachment

Pre-plus disease indicates posterior pole tortuosity and dilatation that are not sufficiently abnormal to reach the criteria of plus disease, but is nevertheless greater than that regarded as normal. It may or may not progress to plus disease.

Plus disease can be present as a major complicating factor at any stage. It is characterized by:

- Significant level of venous dilation and arteriolar tortuosity of the posterior retinal vessels. This reflects the increase of blood flow through the retina
- Two quadrants of the eye retina must be involved for the changes to be characterized as plus disease.

Associated changes may include:

- Iris vascular engorgement
- Poor pupillary dilatation (rigid pupil)

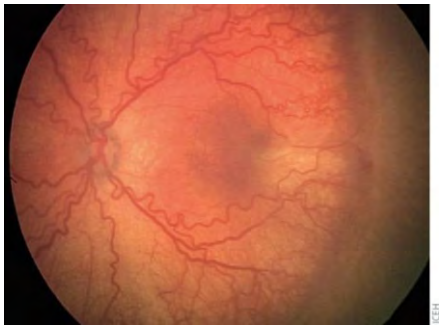

- Vitreous haze and anterior chamber haze

Aggressive posterior ROP (AP-ROP) is nearly always in zone I. The proliferating blood vessels are flat and difficult to see, and plus disease is always present. It is very important to recognize AP-ROP as it can progress extremely quickly to retinal detachment. Treatment should be given within 48 hours.

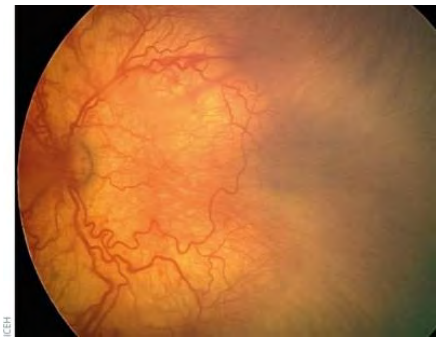

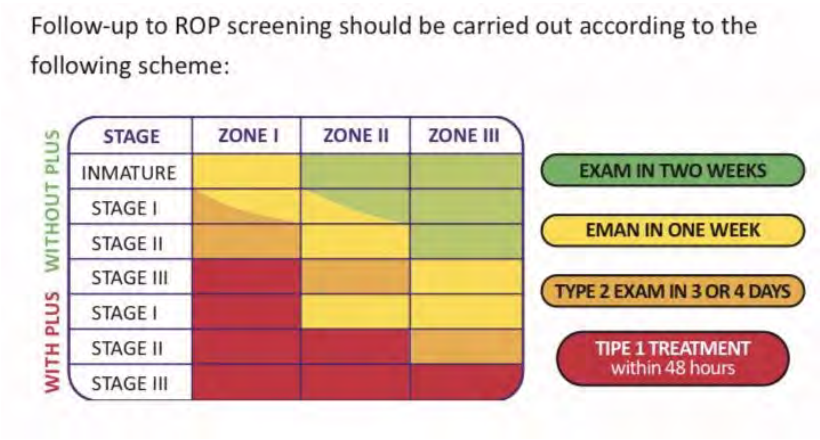

RESULTS

We report all the ROP screening records from our hospital from February 2021 to September 2021, with a total of 100 infants. The distribution was very similar in both genders, being 18 females and 20 males. The mean GA at delivery was 30.56 ± 2.33 weeks and the mean BW was 1287.90 ± 338.52 gms. Throughout this period, 38% of the screenings were detected with some degree of ROP on either eye, which represents 19 of 50 newborns; 91.76% being bilateral(17/19).

Table 1. Incidence or ROP according to gender

Gender	No of cases
Male	20
Female	18

The distribution based on the ROP stage at the time of evaluation was: 18infants were on stage 1, 14 on stage 2, 6 on stage 3.

Table 2. Distribution of ROP according to the stage

ROP Stage	No. Of cases
Stage 1	18
Stage 2	14
Stage 3	6
Stage 4	0
Stage 5	0

Table 3.Distribution according to birth weight

Birth weight	No of patients
<1000	6
1000-1500	18
1500-2000	14

Table 4. Distribution according to gestational age

Gestational age	No of patients
<28 weeks	14
28-32 weeks	22
>32 weeks	4

Table 5. Various risk factors associated with ROP

Risk factor associated	No of patients
Supplement oxygen	28
PCV given	4
Sepsis	2

Apnea	4
RDS	4
IVH	2
Phototherapy	14

DISCUSSION

In this retrospective study we estimated the incidence of ROP among at-risk infants coming to the OPD of Department of ophthalmology, JLN Medical College, Ajmer. Infants with birth-weights ≤ 2000 grams and Gestational Age ≤ 32 weeks and infants with gestational age of more than 32 weeks with sickness like need of prolonged oxygen therapy, need for phototherapy, apnea of prematurity, anemia, blood transfusion and neonatal sepsis were included. These infants were subjected to periodic ophthalmological evaluation, retinal evaluation was done with indirect ophthalmoscope for detection of ROP until full retinal Vascularization occurred. A total of 100 eligible infants completed the full protocol during the period of study.

Six infants in this study developed Severe ROP for which they were referred to higher centre for further treatment. Those infants who did not require intervention and were regularly followed till ROP regression or Vascularization of peripheral retina.

Improved survival of premature infants of gestational age less than 25 weeks gestation and very low birth weight has resulted in an increased incidence of retinopathy of prematurity. All ophthalmologists and neonatologists are aware that the condition of retinopathy of prematurity is potentially blinding condition, but also largely preventable, as in the majority this never progresses beyond the level of mild disease which resolves spontaneously without treatment.

Indirect ophthalmoscopy is a the gold standard technique for retinopathy of prematurity screening. However digital imaging has also emerged as a potential alternative. The RetCam 120 (Massie Research Laboratory Inc., Dublin, California) is a digital retinal camera in pediatric ophthalmology for the photo-documentation of retinal conditions in infants. It produces excellent

reproducible images and its advantage over conventional indirect ophthalmoscopy is that of data and image recording and also its ease of use.

The presence of threshold disease signals the need for treatment. Threshold disease is defined by the Cryotherapy for Retinopathy of Prematurity (CRYO-ROP) Study as at least five continuous or eight cumulative clock hours of Stage 3 retinopathy of prematurity in zone I or II with plus disease. A general ophthalmologist who is screening the babies should be able to identify the threshold disease so the patient is referred for further treatment, as there is short window of opportunity during which treatment can be effective so timely screening of this condition is utmost important.

A protocol has been developed at our institute for the training of general ophthalmologist in techniques of ROP screening. Here a patient's fundus is first assessed by a general ophthalmologist and then cross examined by the Retina specialist working at our institute. Routine educational programs are being held by the retina specialist for the further learning of a general ophthalmologist about ROP to help them in accurate screening of babies who are at high risk.

CONCLUSIONS

In conclusion, ST-ROP diagnosis in preterm infants is not uncommon in India and other developing countries. If detected late or untreated, severe squeal can result in irreversible blindness and all the psychosocial, educational and economic implications. Therefore the minimum necessity is that all babies at risk of ST-ROP are screened and treated. Training of ophthalmologists in the technique of screening for retinopathy of prematurity and the recognition of the disease should not be overlooked so that a larger pool of ophthalmologists can perform screening in the peripheral hospitals. Whilst indirect ophthalmoscopy is the gold standard examination device, RetCam digital image systems are becoming increasingly important. The application of telemedicine to retinopathy of prematurity screening is encouraging and positive and in larger neonatal units telemedicine may almost certainly play a much bigger role in the future.

REFERENCES

1. Dogra, Mangat Ram; Katoch, Deeksha Retinopathy of Prematurity, Indian Journal of Ophthalmology: September 2017 - Volume 65 - Issue 9 - p 782-784 doi: 10.4103/ijo.IJO_783_17

2. Sanghi G, Dogra MR, Katoch D, Gupta A. Aggressive posterior retinopathy of prematurity: Risk factors for retinal detachment despite confluent laser photocoagulation Am J Ophthalmol. 2013;155:159–64

3. Quinn GE, Dobson V, Kivlin J, Kaufman LM, Repka MX, Reynolds JD, et al Prevalence of myopia between 3 months and 5 1/2 years in preterm infants with and without retinopathy of prematurity. Cryotherapy for retinopathy of prematurity cooperative group Ophthalmology. 1998;105:1292–300

4. Vinekar A, Dogra MR, Sangtam T, Narang A, Gupta A. Retinopathy of prematurity in Asian Indian babies weighing greater than 1250 grams at birth: Ten year data from a tertiary care center in a developing country Indian J Ophthalmol. 2007;55:331–6

Recurrent Pleomorphic Adenoma

Dr. Rohit Khatri, Dr. Rakesh Porwal, Dr. Sanjeev Nainiwal

Department of Ophthalmology, J.L.N. Medical College and Hospital, Ajmer, Rajasthan

E-mail:dr.rakeshporwal@gmail.com

Pleomorphic adenoma is the most common epithelial tumor of the lacrimal gland in adults[1]. It is managed by surgical excision. Incomplete removal can lead to recurrence or malignant transformation. High index of suspicion is necessary for prompt diagnosis in younger after surgically removal . We describe a case of lacrimal gland pleomorphic adenoma (LGPA) in a 28-year male which recurrent in nature and emphasize the importance of CT and MRI scan in the diagnosis of extension of recurrence LGPA in young male.

CASE REPORT: A 28 yr old male presented with protrusion of right eye with growing mass in superotemporal orbital region since 3 yr and superonasal orbital region since 1 & 1/2 yr which is gradual in nature, slow continuous progressive, painless, unilateral with limitation of eye movement and diminished visual acuity (Figure 1). He also complain redness and pain in same eye and difficulty to close the eye.

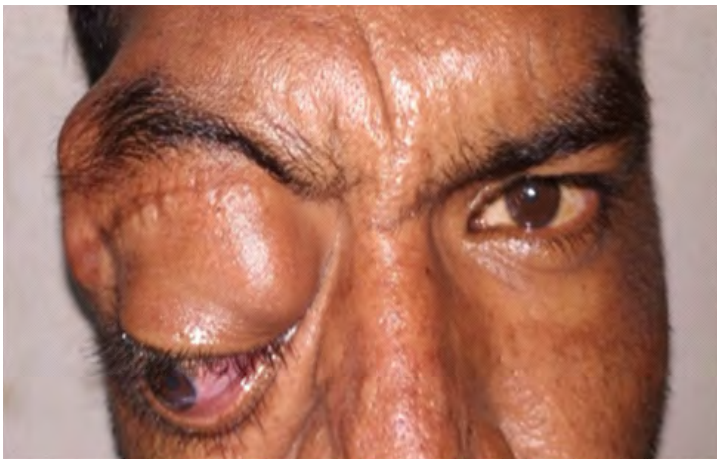

Figure 1. Protrusion of right eye with growing mass.

Past History

There was a history of same constitutional symptoms firstly in 2010 and surgically excised and diagnosed as a pleomorphic adenoma of lacrimal gland. Again he complains swelling in same region in 2013 and surgically removed again and diagnosed with pleomorphic adenoma of lacrimal gland with no malignant transformation. So he was operated two times for this tumor in 2010 and 2013.

General Examination

He is well nourished, average built, well oriented to time, place, and person. Systemic examination is in normal limit. No lymphadenopathy in preauricular and submandibular lymph nodes area.

Ocular Examination

Inspection: Eye ball show displacement of globe with proptosis (infero-lateral globe displacement), non-axial in direction, down and out, unilateral with no peri orbital inflammation, lagophthalmos with surgical scar mark on upper lid medial to laterally showing his previous exicisional surgery.

Palpation: Mass show firm consistency in retropulsion, no orbital thrill, lobular, non tender, non reducible with no supraorbital anesthesia.

Auscultation: No bruit found.

Transillumionation: Dark shadow effect.

Ocular examination revealed a visual acuity of finger count 2 meter in concern eye with diplopia and 6/6 on the Snellen's chart in left eye. Anterior segment examination show conjunctival congestion and chemosis. Cornea show inferior punctate epithelial defect with infiltration nasally with decreased corneal sensation. The proptosis measured using the Hertel exophthalmometer showed readings of 25 mm for the left eye and 19 mm for the right eye. Fundus show glow with media clear, disc temporal pallor, vessel normal, choroidal folds with ERM.

The ocular movement of the right eye was restricted in upward and temporal gaze. Intraocular pressure and visual fields were within normal limits.

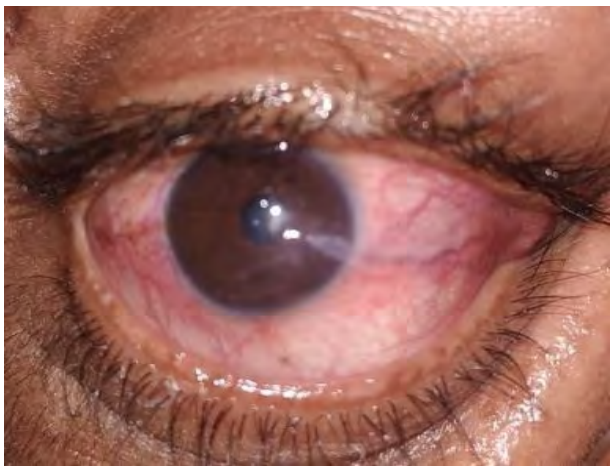

Figure 2. Right eye showing proptosis, conjunctival congestion, chemosis.

Investigations

A CT scan show multiloculated hypodense lesion with cystic and slight hyper attenuating content

seen in right orbit and periorbital region causing proptosis. The lesion show subtle <10 HU enhancement. The lesion involves the intraconal, extraconal fat, periorbital extension with involvement of superior rectus, lateral rectus and superior oblique orbital muscles. Optic nerve is stretched but well preserved. Lacrimal gland is not separately identified. The right orbital roof and lateral wall remodeling seen with scalloping, thinning and focal dehiscence in the roof and focal defect seen in lateral wall.

A MRI of right eye orbit show numerous enhancing round to oval solid lesions are seen in right orbit involving extraconal and extraconal compartments, encasing and compressing optic nerve, eye ball and extra-ocular muscles. Posteriorly lesions are extending up to orbital apex. The lesions are also seen in pre-orbital region and fronto-temporal soft tissues involving temporalis muscle. Mild right proptosis is seen with eye ball displaced infero-laterally. Largest lesion measures approx. 29x24 mm at supero-medial aspect.

Figures 3 to 7 show extension of the adenomas in different compartment of eye.

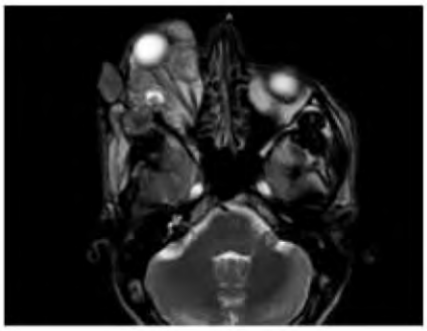

Figure 3

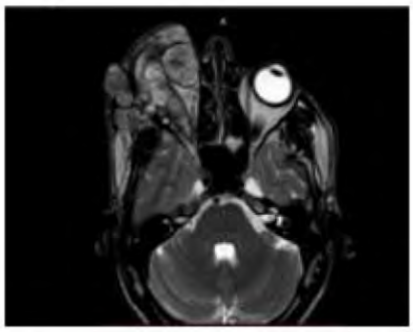

Figure 4

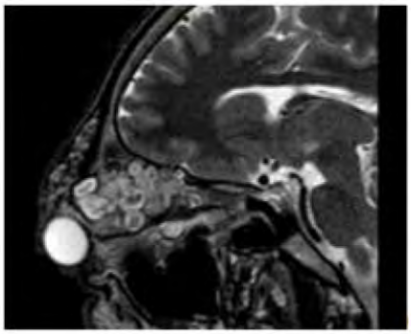

Figure 5

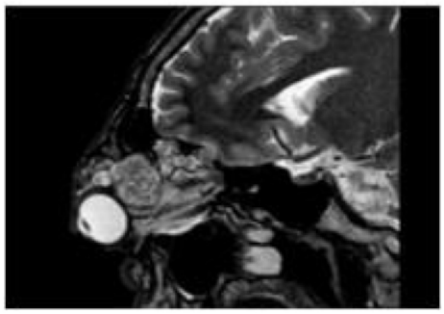

Figure 6

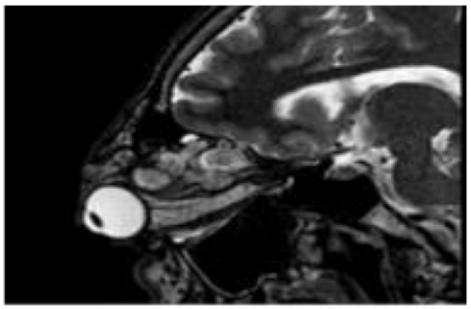

Figure 7

Treatment advised: Complete surgical excision with infiltration tissue resection (complete exenteration of infiltration tissue) with excisional biopsy through anterior and lateral orbitotomy approach.

DISCUSSION

LGPA is a benign, slow-growing, epithelial tumour[1]. It is a well-circumscribed and pseudo-encapsulated superotemporal mass. It can be differentiated from a malignant lesion by the absence of associated pain and bony erosion. LGPA is commonly seen in young and middle age group in fourth and fifth decade. Orbital lobe of the lacrimal gland is involved in 90% of the cases[2]. LGPA can rarely arise from the palpebral lobe or an ectopic lacrimal tissue[3]. LGPA show PLAG1 transcription factor gene and HMGA2 growth regulation and cell proliferation genetic alternation. A CT and MRI scan aids in initial localization and characterization of the tumor. It can help in differentiating benign from malignant lesions, with respect to bony erosion and molding and associated calcification. On histopathology, epithelial and connective tissue elements are seen which show pleomorphism. This epithelial tumor is derived from the ducts of

the gland and shows a double layer of cuboidal cells. The innermost layer of cells may undergo metaplasia resembling myxomatous, fibroblastic, cartilaginous or even osseous tissue with areas of hyalinization. A pseudo capsule is formed, consisting of condensation of connective tissue and may be adherent to the periosteum. This may be invaded by the tumor and if the pseudocapsule is not incompletely removed on excision, recurrence usually follows. Recurrence also occurs in fine needle biopsy, needle track in biopsy, incomplete removal of tumors, incomplete removal of capsule and capsular breach during surgery.

The chances of recurrence 5 years postoperatively are 3% if completely excised with an intact capsule and 30% if incompletely removed[4]. LGPA can serve as a locus for future development of malignant epithelial neoplasm. Around 10% of lacrimal gland tumors become malignant within 20 years of diagnosis and it increases to up to 20% after 30 years[52]. Excisional biopsy is the definitive treatment. Anterior orbitotomy is the preferred route of surgery for access to the anterior extraconal orbital space (palpebral lobe lesions). Lateral orbitotomy is an approach for deeper orbital lesions that could not be accessed through an anterior incision or require larger exposure (orbital lobe lesions). Recurrence can occur if the tumor is incompletely excised or if an incisional biopsy was performed preoperatively.

REFERENCES

1. Shields CL, Shields JA, Eagle RC, et al. Clinicopathologic review of 142 cases of lacrimal gland lesions. Ophthalmology 1989;2013:431–5

2. Font RLGJ. Epithelial tumors of the lacrimal gland: an analysis of 265 cases. In: Jakobiec F, ed. Ocular and adnexal tumors. Birmingham, AL: Aesculapius, 1978:787–805

3. Vangveeravong S, Katz SE, Rootman J, et al. Tumors arising in the palpebral lobe of the lacrimal gland. Ophthalmology 1996;2013:1606–12

4. Gupta S, Garg S, Singh S, et al. Pleomorphic adenoma of lacrimal gland in a 5-year-old child: diagnosed on aspiration cytology. Diagn Cytopathol: 18 Nov 2011. doi: 10.1002/dc.21854

CASE REPORT

Early Presentation of Advanced Diabetic Retinopathy: A Diagnostic Dilemma

Dr. Shruti Bihani

PG Resident, Kurnool Medical College, Kurnool, Andhra Pradesh

E-mail: shrutibihani07@gmail.com

ABSTRACT

A 46-year-old male presented with complaints of decreased vision in both eyes. Decrease in vision was sudden, painless in the left eye (LE) with best-corrected visual acuity (BCVA) of hand movement (HM). Decrease in vision was gradual, painless and progressive in the right eye (RE) with BCVA of counting finger (CF) ½ meter. He was diagnosed with diabetes 1 year back and has been taking oral hypoglycemic agents regularly and had moderate glycolic control. Thorough eye examination revealed macular hole with traction retinal detachment in superotemporal quadrant in RE and combined rhegmatogenous and traction retinal detachment in LE. He did not undergo any ophthalmic examination earlier and directly presented with advanced diabetic eye disease.

INTRODUCTION

India being, rapidly becoming diabetic capital of the world, cases of diabetic retinopathy are also rising. Duration of diabetes is the biggest risk factor in the incidence of retinopathy. Incidence of retinopathy is high in juvenile onset diabetes compared to adult onset. Regular ophthalmic examination helps in early diagnosis and treatment of diabetic retinopathy, thus preventing risk of severe visual loss.

CASE REPORT

A 46 year old male presented with chief complaints of decreased vision in both eyes. BCVA was counting fingers 1/2 meter in RE and hand movements in LE. Decrease in vision was sudden

and painless in left eye 2 months back. In right eye, decreased vision was gradual, painless and progressive in nature since 1 month. Floaters present in left eye. No diplopia, colored halos, photophobia, redness, watering was noticed. Patient had history of using herbal eye drops 1 month back. No history of ocular trauma, ocular surgery, infection. He was diagnosed with type-2 diabetes mellitus 1 year back and has been using oral hypoglycemic agents regularly since then, had moderate glycolic control. He did not undergo any ophthalmic examination in the last 1 year. On slit lamp examination, BE showed early nasal pterygium, clear cornea, anterior chamber was of normal depth, iris pattern was normal, pupil was normal in size, sluggishly reacting to light and grayish white lens. IOP in RE and LE 13 and 10 mm of Hg respectively. Fundus examination of right eye revealed optic disc was normal in shape, size and margin with CDR of 0.3:1. Old vascular occlusion with macular hole with traction retinal detachment in superotemporal quadrant (Figure 1).

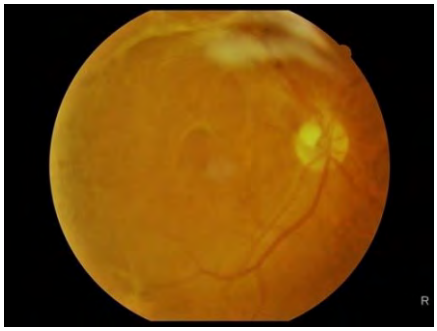

Figure 1- RE fundus showing old vascular occlusion with macular hole with traction retinal detachment in superotemporal quadrant.

Fundus examination of the left eye revealed optic disc normal in shape, size and margin with CDR of 0.3:1. Combined rhegmatogenous and traction retinal detachment with fibrovascular proliferation (Figure 2).

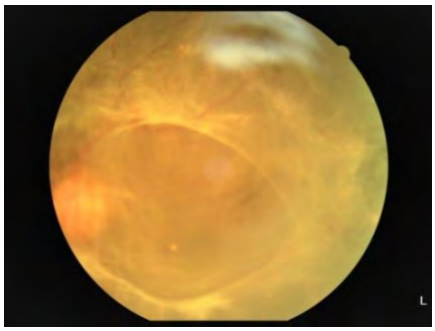

Figure 2- LE fundus showing combined rhegmatogenous and traction RD with fibrovascular proliferation.

USG B scan also revealed RE supero-temporal tractional RD and LE combined rhegmatogenous and tractional RD (Figures 3 and 4).

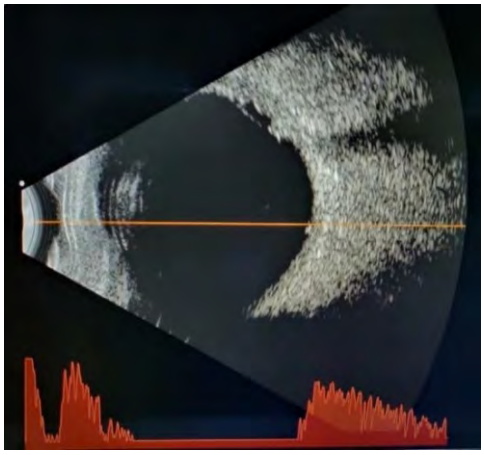

Figure 3. RE B Scan showing traction RD in supero-temporal quadrant.

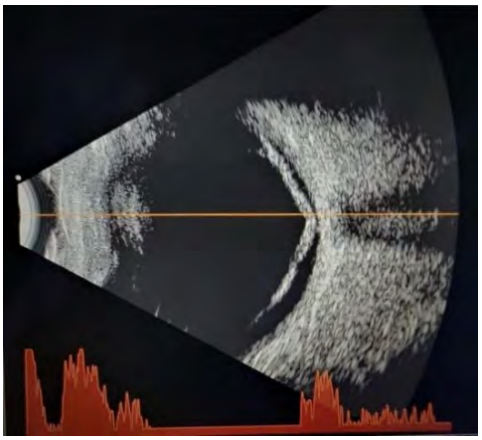

Figure 4. LE USG B scan showing Combined RD.

DISCUSSION

Diabetes can impact the eye and vision by affecting many structures of eye ranging from cornea to retina. Diabetic retinopathy is most visible and important change that takes place in eyes due to diabetes. Longer duration of diabetes increases risk and severity of retinopathy. Nearly 100% of juvenile diabetics develop retinopathy after 20 years of suffering from diabetes. Poor blood sugar level control also impacts the development of retinopathy. Severity of retinopathy is also associated with high triglyceride levels. Non proliferative DR shows early changes such as microaneurysms, intraretinal hemorrhages, venous beading, hard exudates, IRMAs. Proliferative DR is characterized with neovascularization, vitreous haemorrhage, fibrous bands and

progressing to retinal detachment causing severe visual loss. Ophthalmologic treatment is indicated when neovascularization develops, carrying the risk of vitreous haemorrhage and traction retinal detachment. Panretinal photocoagulation improves the balance of retinal oxygen demand and supply and therefore reduces the neovascular stimulus. In case of diabetic macular edema, focal retinal photocoagulation or intravitreal drug injections can be given to stabilize capillary permeability in order to preserve vision. In advanced cases, treatment via pars-plana-vitrectomy has to be evaluated.

Incidence of advanced disease is greatly reduced due to anti-VEGFs and vitrectomy, thus emphasizing on providing better treatment to patients at early stages. Emerging technologies with retinal imaging tools and artificial intelligence have increased access to care for diabetic people. Diabetic retinopathy is a severely debilitating disease which can be prevented with strict control of blood sugar levels, complete ophthalmic examination as soon as patient is diagnosed with type-2 DM and after 3 years in type-1 DM as per new recommendations. Regular eye check-ups will help in early diagnosis and treatment and prevention of severe visual loss.

REFERENCES

1. Ebneter A, Zinkernagel MS. Novelties in Diabetic Retinopathy. Endocr Dev. 2016;31:84-96. doi: 10.1159/000439391. Epub 2016 Jan 19. PMID: 26824524.

2. Rhegmatogenous Retinal Detachment: Features, Part 1. EyeNet December 2018. Link: www.aao.org/eyenet/article/rhegmatogenous-retinal-detachment-features-part-1#disqus_thread

3. Lyford T, Sheppard J. Diabetic Eye Disease: Advancements in Technology, Detection, and Access to Care. Sr Care Pharm. 2020 Jun 1;35(6):266-272. doi: 10.4140/TCP.n.2020.266. PMID: 32456756.

4. Helbig, Horst; Sutter, Florian K P (2004). Surgical treatment of diabetic retinopathy. Graefe's Archive for Clinical & Experimental Ophthalmol. 2004, 242(8):704-709. DOI: https://doi.org/10.1007/s00417-004-0977-9

CASE REPORT

Intra-Orbital Wooden Foreign Body in Mobile Phone User

Dr. R. K. Verma

Aditi Eye Hospital, Chitrakoot Scheme, Jaipur

E-mail: rkvophthal@rediffmail.com

Cell phone use while driving has become a leading cause of vehicle crashes over the last two decades. We present a case of 28 yrs male was travelling on a two wheeler and was talking on mobile phone when he collided with a lady carrying fire wood bunch on her head. There was open wound which was managed by local hospital by suturing and dressing. Suture removal was done after ten days. After 20 days he reported to our hospital with permanent swelling on left eye brow and some mass felt on touching the area with mild pain and discomfort. On examination non - tender subcutaneous hard mass was palpated at the medial and lower side of left eyebrow which was immobile with rough protuberance. Extra-ocular muscles, visual acuity, were intact, there was no exophthalmos or enophthalmos, eyelids were mobile, and facial bones were intact without evidence of bony step off. Intra-ocular pressure and slit lamp examination was within normal limits.

Operative intervention was undertaken for exploration under local infiltration anesthesia. Intra-operatively, initial incision resulted in the drainage of a collection of purulent fluid underneath.. Further exploration revealed a 54-mm irregular linear wooden foreign body in the post septal space (Figure 1 & 2). The area was copiously irrigated with betadine, and normal saline and a small pack was placed to attain hemostasis. Wound was sutured with 5-0 silk suture. Intravenous antibiotics and topical ophthalmic ointment was prescribed. On postoperative day 1, the patient had significant clinical improvement. Follow-up at 2 weeks showed complete resolution (Figure 3).

Figures 1 & 2: A large irregular linear wooden foreign body removed from post septal space.

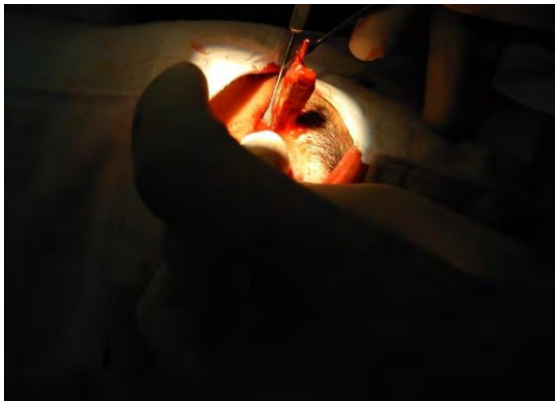

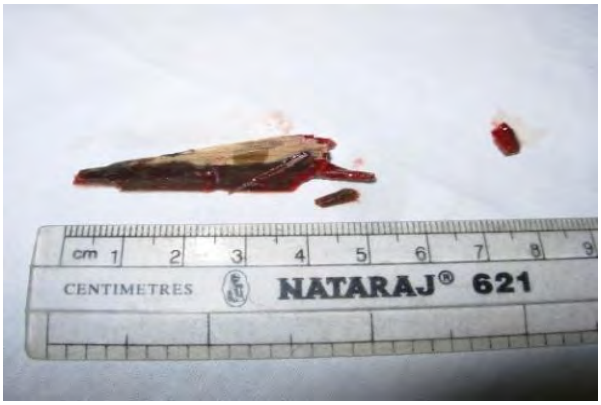

Figure 3: showing complete resolution.

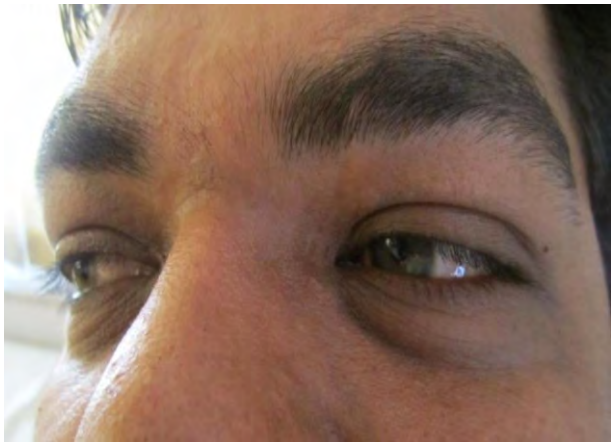

DISCUSSION

There is no specific symptom diagnostic for retained intra-orbital foreign bodies. Common symptoms and signs include persistently red and irritated eye, diplopia, decreased visual acuity, localized pain, pressure or eyelid tightness, and disruption in ocular motility. This can result in a host of significant ocular complications including loss of vision, globe rupture, entrapment, and optic neuropathy. A high degree of suspicion must be maintained for the possibility in patients with a history of peri-ocular trauma who demonstrate peri-orbital cellulitis, inflammation, or other ocular symptoms. Organic foreign bodies have a higher rate of sight-threatening complications and infections than nonorganic foreign bodies, and while recommendations for surgical removal may vary on the basis of the composition of the foreign body as well as their

intra-orbital location, appropriate broad-spectrum antibiotic treatment as well as anti-tetanus prophylaxis is generally accepted.

Imaging studies for retained wooden and other radio-opaque intra-orbital foreign bodies often do not clearly assist with the diagnosis and these materials are often missed. Wooden intra-orbital foreign bodies present a unique radiologic diagnostic challenge due to their varied appearance with different imaging modalities and other factors including size, shape, porosity, type, density, and especially whether the foreign body is wet or dry. While plain films are frequently performed because of their cost-effectiveness and accessibility, they may be useful only in detecting metallic intra-orbital foreign bodies particularly prior to magnetic resonance imaging but are futile in detecting wooden and other organic foreign bodies. Ultrasound is occasionally a helpful diagnostic adjunct due to the hyper-echoic foci of wood and its acoustic shadow, but in situations of orbital trauma where there is gas in the orbit, ultrasound is insensitive in detecting wood due to interference of air. While CT is currently the imaging modality of choice for wooden intra-orbital foreign bodies, numerous similar reports have demonstrated that the signal from wooden materials is often mistaken for fat or air.

Mobile phone use while driving is common but it is widely considered dangerous due to its potential for causing distracted driving and crashes. Due to the number of crashes that are related to conducting calls on a phone and texting while driving, some jurisdictions have made the use of calling on a phone while driving illegal and punishable act, In the United States, automobile crashes due to distracted driving are increasing. The leading cause of distracted driving is cell phones. In 2015, six hundred and sixty thousand drivers in the United States were estimated to use cell phones each day, while driving behind the wheel during daylight hours. Cell phone use while driving has become a leading cause of vehicle crashes over the last two decades. Using a cell phone while driving increases the driver's risk of causing a crash.. Drivers are distracted, decreasing the driver's awareness on the road, leading to more car crashes. When drivers talk on cell phones the risk of an automobile crash resulting in hospitalization is four times higher than when not talking on a cell phone. Drivers who text when behind the wheel, are twenty-three times more likely to have an automobile crash. One out of every four automobile crashes in the

United States are caused by texting while driving. Indian government has recently implemented strict laws in regards to using cell phones while driving, there is more to be done.

REFERENCES

1.Liu D. Common denominators in retained orbital wooden foreign body. Ophthal Plast Reconstr Surg. 2010;26:454–8.

2. Fulcher TP, McNab AA, Sullivan TJ. Clinical features and management of intraorbital foreign bodies. Ophthalmology. 2002;109:494–500.

3. Holt GR, Holt JE. Management of orbital trauma and foreign bodies. Otolaryngol Clin North Am. 1988;21:35–52.

4. Shelsta HN, Bilyk JR, Rubin PAD, et al. Wooden intraorbital foreign body injuries: clinical characteristics and outcomes of 23 patients. Ophthal Plast Reconstr Surg. 2010;26(4):238–44.

5. McEvoy, S. P.; Stevenson, M. R.; McCartt, A. T.; Woodward, M.; Haworth, C.; Palamara, P.; Cercarelli, R. (2005). Role of mobile phones in motor vehicle crashes resulting in hospital attendance: A case-crossover study. BMJ. 331(7514)

6. David; Drews, Frank; Crouch, Dennis (2003). "Fatal Distraction? A Comparison of the Cell-Phone Driver and The Drunk Driver" (PDF). University of Utah Department of Psychology. Archived from the original (PDF) on 2009-04-11.

7. Jeffrey K. Caird; et al. (October 25, 2004). "Effects of cellular telephones on driving behaviour and crash risk: results of meta-analysis" (PDF). CAA Foundation for Traffic Safety. Archived from the original (PDF) on February 16, 2008.

Choroidal Melanoma Presenting with Secondary Glaucoma: A Case Series

Dr. Ashok K. Meena, Dr. Jasram Meena, Dr. Renu Meena,
Dr. Meenal Gupta, Dr. Anand Goyal
Department of Ophthalmology, Govt. Medical College, Kota, Rajasthan
E-mail: dr.ashokmeena10@gmail.com

INTRODUCTION

Uveal tract comprise melanomas of the iris, ciliary body and the choroid. The choroid melanomas are more frequent to occur in comparison to iris and ciliary body melanomas. Choroid melanoma though rare, is the most common occurring intraocular malignancy amongst the adults. Incidence of occurrence of choroid melanoma is around 20 per million cases per year globally. The uveal tract pigment producing melanocytes are the origin for the melanoma in the eye. Melanomas tend to commonly arise from sixth decade of age with increasing incidence with progressive age[1]. We herewith report the case series of two cases of choroidal melanoma who were presented with secondary glaucoma which were managed at our tertiary eye care centre at Kota.

CASE REPORTS

CASE 1: A Hindu male patient 47 years old presented in ophthalmology department of G.M.C. Kota with chief complaints of pain, redness and diminution of vision in right eye for last 20 days. No significant past and family history. His general and systemic examination was normal. Ophthalmic examination was carried out, distant vision in right eye was PL present and PR inaccurate in all four quadrant while in left eye distant vision was 6/18-6/12 with pin hole. IOP in right eye was 37.5 mmHg and in left eye 14.6 mmHg. Anterior segment examination with Slit lamp of right eye showed hazy cornea, shallow anterior chamber semidilated, fixed and nonreacting to light pupil with intumescent cataract and left eye showed early lenticular change with normal pupil. Binocular Indirect ophthalmoscopy of the right eye showed no fundus glow and fundus details not visible while left eye showed normal fundus details.

Patient was initially diagnosed as lens induced glaucoma and advised for cataract extraction with trabeculectomy under LA with poor GVP explained for right eye but during operation after removal of cataractous lens ,there was white reflex seen so without implanting IOL special investigations were performed. USG right eye showed a intraocular mass arising from

anteromedial aspect of globe ,was well demarcated and cystic mass measuring16.3mm x12.9mm with vascular band arising from posterior wall.

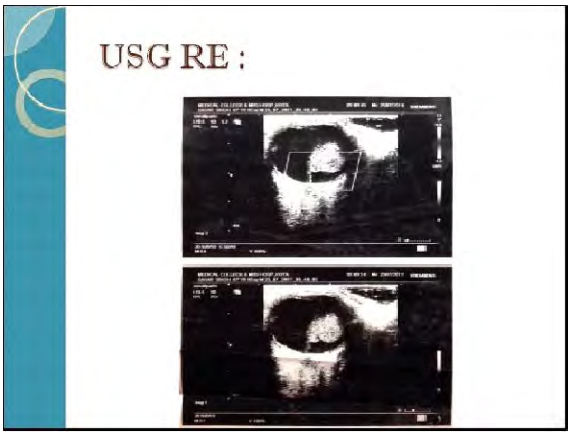

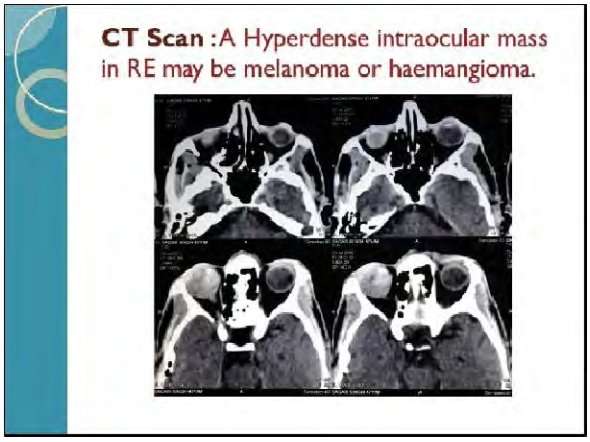

MRI SCAN: it reveals an irregular T1 hyperintense endophyte mass lesion arising from anteromedial aspect of RE most probably uveal melanoma. This associated with vitreous hemorrhage & deformed right globe. No extra-ocular extension of mass seen.

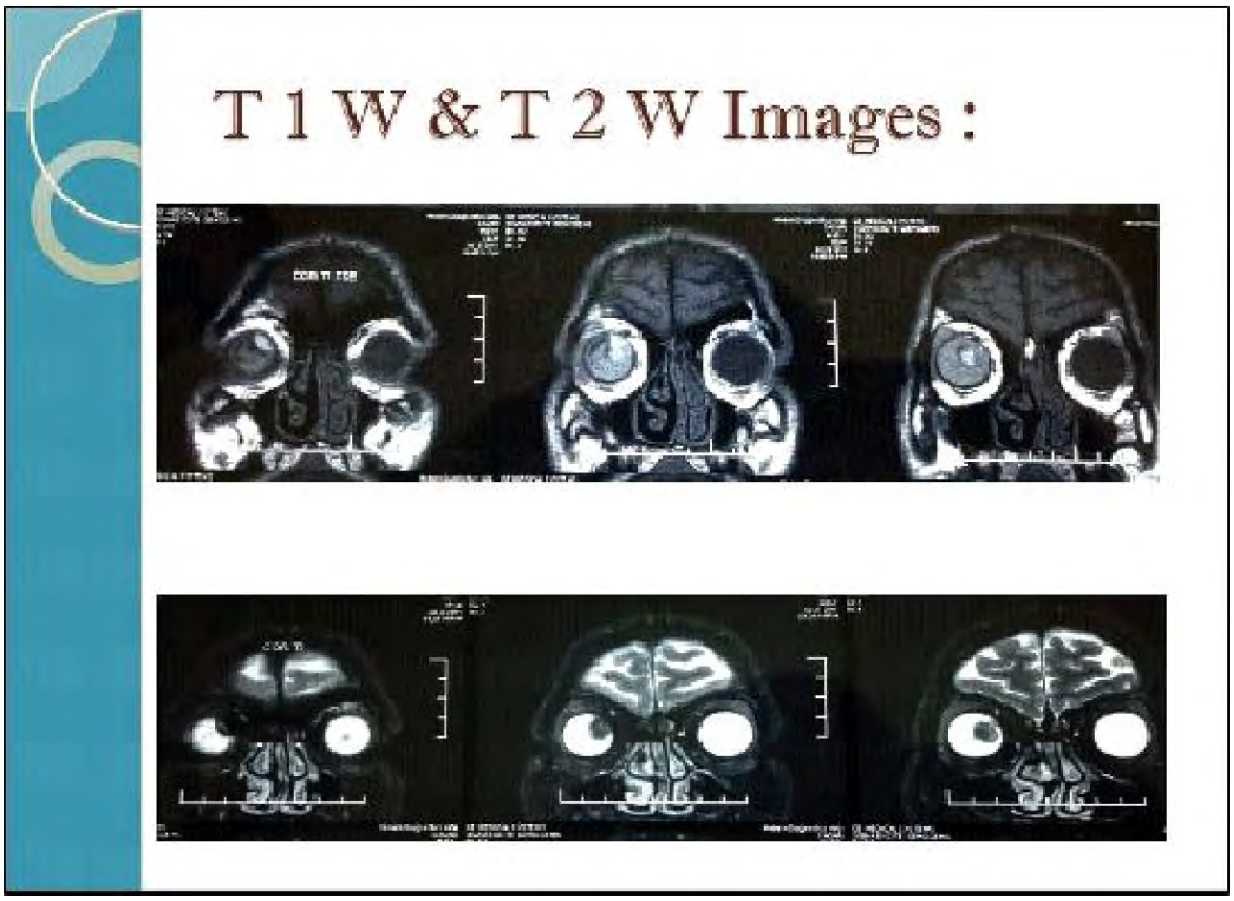

USG Guided FNAC: Cytosmear showed cell in cluster & round to spindle shape with pleomorphism with pigment suggestive of melanotic melanoma.

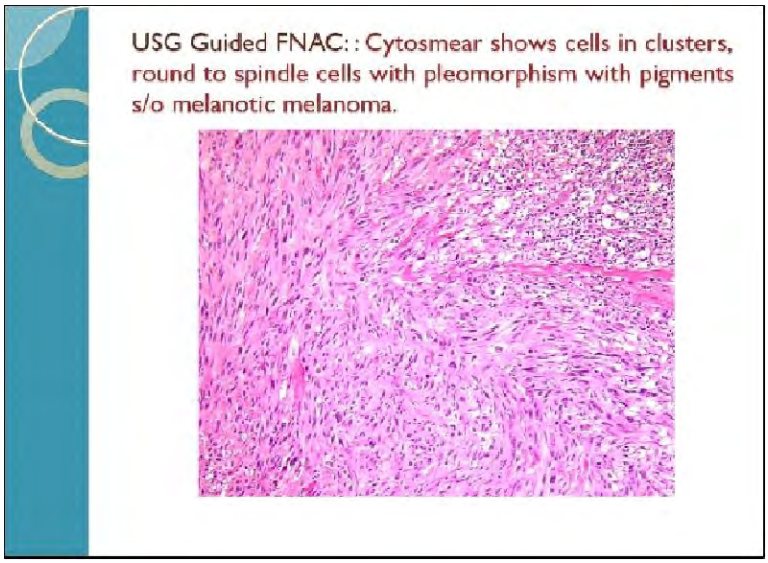

After complete examination case was diagnosed as choroidal melanoma of right eye. The patient undergone right eye enucleation under LA and postoperative systemic antibiotic, analgesic and topical antibiotic was given. After a month patient was given artificial prosthesis on subsequent follow up visit.

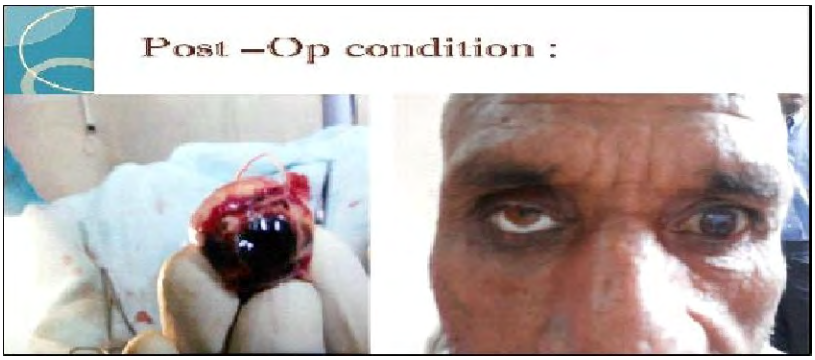

CASE 2.

A 60 years old male patient presented with loss of vision with eye ache and redness of right eye. Patient was asymptomatic 6 months back then he developed gradual progressive diminution of vision which was followed by eye ache, patient also gave history of metamorphopsia. Then vision was completely lost 3 months back. Past and family history was insignificant. Vision in right eye was PL absent and IOP was 29 mmHg and in left eye vision was 6/18 and 10P was 18

mmHg. Anterior segment examination of right eye showed corneal edema with KP's on endothelium, shallow anterior chamber and pupil mid dilated & fix and non-reacting to light. Cells in AC. Posterior segment examination of right eye showed yellowish reflex and rest not clearly visible and left eye details were normal. Routine investigations including ALP, LDH & GGT were normal. Patient was Hepatitis Bs Antigen positive. B-SCAN of right eye showed Mushroom shaped mass with internal vascularity.

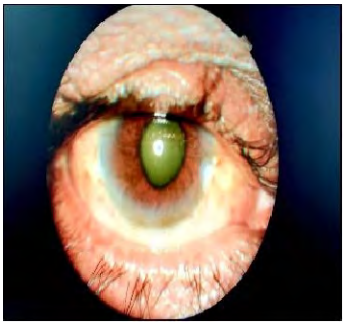

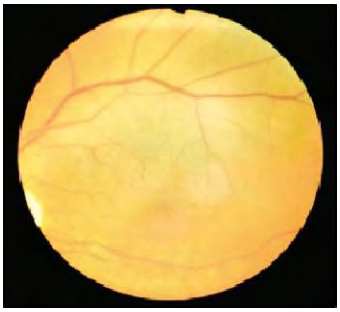

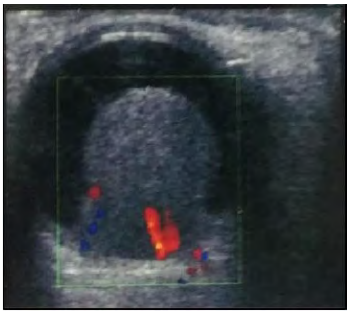

MRI SCAN T1 weighted image showed hyper intense while T2 & DWI images showed hypo intense mass lesion.

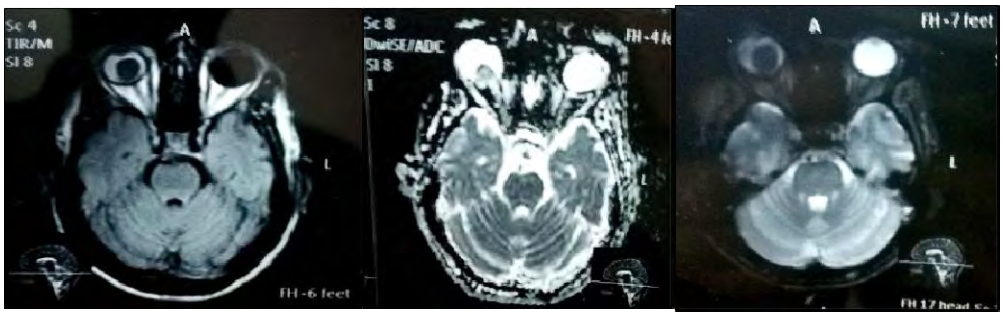

After radiological and metastatic evaluation patient diagnosed as case of choroidal melanoma with secondary glaucoma & undergone enucleation with allogenic sclera over a sphere silicone [18mm size] prosthesis implant is done. To maintain conjunctival sac a conformer is placed.

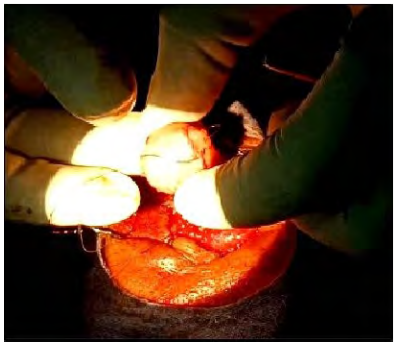

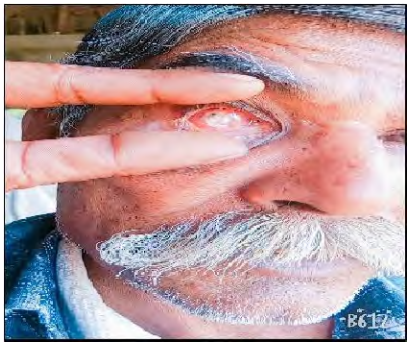

Post-operative evaluation of eye ball showed mushroom shaped mass protruding from choroid behind the lens.

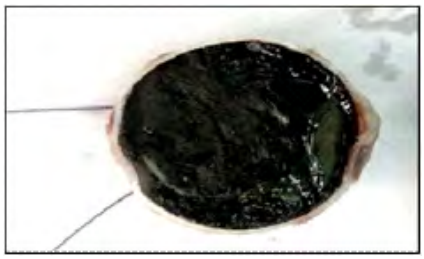

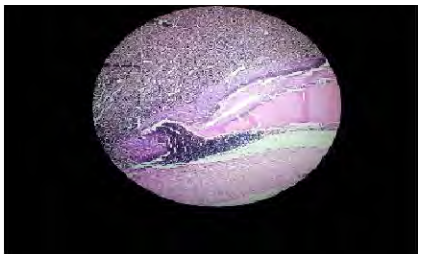

Histo-pathological examination of mass showed epitheloid type of choroidal malignant melanoma.

DISCUSSION

Melanomas of the uveal tract can be divided into the lesion of the anterior and the posterior tract, the anterior tract melanoma involve the iris where as the posterior tract melanomas involve the ciliary body and the choroid layer. Malignant melanomas of the uvea are frequented more often in the choroid and the ciliary body in comparison to the iris. Melanomas are highly malignant epithelial cancers [1]. Melanomas tend to commonly arise from 70 years of age, however no age is spared [2,3]. Clinically the presentation of choroidal melanomas is variable. In general anterior choroidal melanomas have a delayed presentation because of slow growth however clinical signs and symptoms can present earlier. Patients of choroidal melanoma usually present with blurring of vision. Patient may experience painless and progressive visual field loss as the peripheral melanoma enlarges. Floaters and at times balls of light are experienced by subjects in case of necrosis of tumor or hemorrhage in the adjoining areas. Severe pain may be experienced with impingement of tumor mass on ciliary nerves or due to acute angle closure glaucoma. Choroid layer being devoid of lymphatics hence majority of the choroidal melanomas spread by hemotogenous route mainly to the liver [4].

Choroidal melanomas have variable pigmentation from being highly pigmented to being amelontic in appearance. The choroidal melanomas irregular, slate-gray, solid, initially present as dome shaped subretinal nodular circumscribed mass. With more expansive behaviour they tend to form irregular bilobular to multilobular configurations, some of become mushroom shaped after

breaching the Bruch's membrane.

Traditionally on histology the choroid melanoma has been categorized into three divisions namely spindle type A, spindle type B and epitheloid type. The modified **Callendars classification** of uveal melanomas has four categories [5]. 1. Spindle cell type tumors comprising 45% of all choroidal melanomas. 2. Pure epitheloid cell Melanomas 5% (rare occurrence). 3. Mixed cell melanoma 45% (comprising of spindle cell and epitheloid cell types). 4. Necrotic-iris melanomas have the best prognosis where as the ciliary body melanomas have the worst prognosis. Iris melanomas are the least common. Necrotic melanoma 5% (predominant cell type unrecognizable). The overall prognosis of malignant melanoma of the uvea is based on several factors; however, the malignant melanoma can be said to have an intermediate prognosis, mortality being close to 50%, 15years after enucleation [6].

TREATMENT

Present day management trend generally centers on cautious conservative maximum vision sparing approach. Tumors of the posterior segment not readily visible of size less than 2.0-2.5 mm in elevation and <10 mm in diameter should be left for observation, sequential photograph and ultrasounds should be carried out to keep follow up on size. Brachy therapy for tumor less than <10mm elevation and <20mm in diameter supplemented with transpupillary thermotherapy, external beam irradiation for tumors unsuitable for brachytherapy, segmental iridectomy can be used for iris melanomas, a difficult approach but conservative can be transscleral local resection as well as stereo-tactic radio-surgery and finally larger tumors involving the entire globe require enucleation. Exenteration is carried out in case of widespread orbital involvement. Systemic chemotherapy are only advocated in case of positive distant metastasis.[7]

Malignant melanomas of the uvea are frequented more often in the choroid and the ciliary body in comparison to the iris. Symptomatology is extremely variable with a choroid mass. Choroidal melanoma may unusually presents with secondary glaucoma. So general ophthalmologists should be aware of these rare initial manifestations of uveal melanomas as secondary glaucoma. So one should be extremely cautious in such cases and before performing penetrating surgery, special investigations of posterior segm ent like B-SCAN must be performed. Treatment in current scenario is preferably conservative and in most of the cases enucleation recommended.

Conflict of Interest: The authors declared that is no conflict of interest.

REFERENCES

1. Font RL, Spaulding A, Zimmerman LE. Diffuse malignant melanoma of the uveal tract. A clinicopathologic report of 54 cases. Trans Am Acad Ophthalmol Otolaryngol. 1968;72:877-95.

2. Barr CC, McLean IW, Zimmerman LE. Uveal melanoma in children and adolescents. Arch Ophthalmol. 1981;99:2133-36.

3. Broadway D, Lang S, Harper J, Madanat F, Pritchard J, Tarawneh M, et al. Congenital malignant melanoma of the eye. Cancer. 1991;67:2642-52.

4. Kath R, Hayungs J, Bornfeld N, Sauerwein W, Hoffken K, Seeber S. Prognosis and treatment of disseminated uveal melanoma. Cancer. 1993;72:2219-23

5. McLean IW, Zimmerman LE, Evans R. Reappraisal of Callender's spindle A type of malignant melanoma of choroid and ciliary body. Am J Ophthalmol. 1978;86:557-64.

6. McLean IW, Foster WD, Zimmerman LE. Uveal melanoma. Location, size, cell type, and enucleation as risk factors in metastasis. Hum Pathol. 1982;13:123-32.

7. Semenova E, Finger P. Palladium-103 plaque radiation therapy for AJCC T3 and T4 sized choroidal melanoma. JAMA Ophthalmol. 2013;5677

Secrets of Best Running Medical (Ophthalmic) Practice

Dr. Vidushi Sharma, Dr. Suresh K.Pandey
SuVi Eye Institute & Lasik Laser Center,
C 13 Talwandi, Kota, Rajasthan, India
Email:suvieye@gmail.com

A successful doctor (ophthalmologist) needs to be a people's person at heart. Someone who enjoys interacting with all sorts of people. He/ she needs to be truly skilled in art and science of medicine and surgery, as modern medical science has really evolved to a very high level of precision over the last few years, and therefore the patient expectations have also risen dramatically. While it is quite enough to be a good eye surgeon and give good results, to excel, one has to learn good communication skills, strive constantly to give the best surgical results, as well as the best overall experience to the patients.

The 4 C's for successful ophthalmic practice are: competency, communication skills, compassion, and convenience. Good surgical training is the bedrock that no one can do without in today's age. Along with this, it is very important to market the practice, as well as build an excellent team and maintain a healthy work life balance to continue enjoying practice growth. There are many important aspects to being the best at anything. In this write-up, the authors offer valuable pearls for the young ophthalmologist—from personal enrichment to building a practice and dealing with increasing patient loads and the eventual difficult patient.

QUALITIES OF SUCCESSFUL DOCTOR (OPHTHALMOLOGIST)

A good doctor needs to be a people's person at heart. Someone who enjoys interacting with all sorts of people. He/ she needs to be truly skilled in fine ophthalmic surgery, as ocular surgery has really evolved to a very high level of precision over the last few years, and therefore the patient expectations have also risen dramatically. However, in this competitive and demanding world, both the science and technique as well as the art are important. And therefore, while it is quite enough to be a good surgeon and give good results, to excel, one has to learn good communication skills, strive constantly to give the best surgical results, as well as the best overall experience to the patients. Last but not the least, punctuality and keeping up announced timings in the clinic remain important to spread the message among your patients that you are available for your patient to deliver the best possible care.

Young ophthalmologists first and foremost need to learn and fine tune their surgical skills as best as they can, and the earlier, the better. At a young age, without the additional responsibilities of family and children, it is possible to travel to different cities and countries, and get the best possible training. Good surgical training is the bedrock, that no one can do without in today's age. Along with this, young ophthalmologists should also make it a habit to observe their seniors interacting with patients, particularly difficult and demanding patients. If you have plans of having your own practice, then you need to know the basics of financial planning and administration. Observe the facilities that are provided in good practices, and the small things that can make a significant difference to the overall patient satisfaction.

By default, even today most young ophthalmologists end up starting their own practice, though the practice patterns are now changing rapidly, with more emphasis on group practices, shared facilities etc. When one starts a new practice, often they realize that the residency training has not prepared them for this at all. When managing a new ophthalmic practice, the ophthalmologist needs to go beyond clinical and surgical ophthalmology to truly satisfy and manage a patient, and beyond patient management to run an efficient, financially viable growing ophthalmic practice. Someone said that *"The education of the doctor which goes on after he has his degree is the most important part of his education".* At this stage, we need to keenly and quickly learn the basics of practice management, in terms of staffing, administration, providing the right ambience, marketing, communication and patient handling skills etc. in short, while we need to hone our surgical skills during training, we must also focus on our soft skills if we want to run a successful practice.

MANAGING HIGH VOLUME PATIENT WORKLOAD

If you are fortunate enough to have a high volume patient workload in your practice, it often becomes a challenge to give enough time to each patient and fully satisfy them. Here effective communication skills become very important, where you can give all the necessary and relevant information in a short time, and utilize your chair time with the patient most efficiently. However, despite all this, there will be patients and attendants who need repetitive explanations and guidance, and here the role of well-trained staff, and particularly counselors becomes very important. We must utilize the services of well-trained and groomed staff and counselors who can take over the work of explanations and can give the patients more time, thereby reassuring them and satisfying all their queries. Depending on the workload and the practice setting, we can delegate many other tasks to the staff e.g. optometrists who can do more than half the work, or trained technicians who can perform investigations etc. However, it is important to keep motivating the staff regularly to provide their best services to the patients. At the same time, have printed brochures for all common diseases and facilities available in your clinic, that give detailed information to the patients and attendants. Electronic Medical Record (EMR) Systems can also help in managing high volume practices, when used efficiently.

DEALING WITH UNSATISFIED PATIENTS

This is becoming an increasingly difficult but necessary art to master. We must take part of the blame for raising the patient expectations so high, that they have become very difficult to satisfy. A lot of aggressive advertising, tall claims and high surgical costs have convinced the patients that eye surgery is a five minute wonder, where nothing can go wrong, and the patient will get "super-vision". In this scenario, the first thing is to have good counseling for all surgical patients. Adequate chair time needs to be given so that the patient expectations are realistic, and there is no mismatch between their expectations and what can be delivered. Despite these efforts, if a patient ends up dissatisfied with the results, the first thing is to give a patient hearing. Many irate patients often cool down enough with a felling of having been heard and understood. Never try to brush aside their complaint, even if they seem insignificant to you. Patients will seldom create much trouble if the doctor is respectful and sensitive and hears them out, but with become increasingly aggressive of they get the impression that the doctor makes them feel inferior or is too rushed to listen to them. Also, it goes without saying that we must do the best that we can to solve the cause of their dissatisfaction, and be financially considerate while doing so.

IMAGE BUILDING FOR SUCCESSFUL OPHTHALMIC PRACTICE

Marketing and image building is an essential part of practices today, and is no longer considered a dirty word in medicine. However, marketing in medicine bears a greater responsibility to be ethical and appropriate. We owe it to the dignity of our profession to ensure that our marketing is not in poor taste. Marketing is not synonymous with advertising, and aggressive advertising is still controversial among medical circles. Subtle marketing on the other hand is less expensive, often more effective and also acceptable. But with the increasing presence of corporate sector in the medical profession, advertising is here to stay. Marketing in the medical field can initially be cold call type like newspaper advertisements, billboards etc., where we make unsolicited contact with a wide audience. For a new practitioner, this is necessary as he needs to inform the widest possible audience in his area of practice about his services and expertise. Later, one can progress to inbound marketing using the internet and social media for potential customers, giving them a platform to ask queries and know you and your services before they choose you and in-house advertising, where the services available in your practice are prominently displayed in your own premises with clear information and staff is willing and capable to answer any queries related to these services. For a young practitioner, it is important to control the finances in marketing, and after the initial few cold calls, turn to more focused marketing and do not try to "outdo" competitors in advertising. It is also a good idea to organize educational awareness activities and camps at sites of public gatherings, which is a cheap and effective way to market yourself. Finally, you must aim for a scenario, where your satisfied patients become your best marketing tools, because this word of mouth publicity is the strongest and most convincing to potential customers.

To grow professionally among peers, one needs to have good oratorical as well as public relation (PR)/communication skills. Start by attending the meetings of the medial societies in your area and offer to organize one or two activities at special occasions, where you can display your organizational as well as presentation skills. Societies always need young, dynamic people willing to take on responsibilities, without displaying any ego. Remember not to get involved in factional politics, and be respectful to all seniors.

GROWING THE OPHTHALMIC PRACTICE

If you can provide good services, the work is bound to grow. You need to ensure that you deliver not only good surgical results, but also ensure an overall good experience for your patient. This would mean that you focus on all services provided in your practice right from the ease of paring near your practice to the reception, waiting time, comfort in the waiting hall, adequate facilities for drinking water, toilets, refreshments, if needed, reading material to keep them busy while waiting, professional reasonable quick service, cheerful and cooperative staff and an adequate explanation of fall their queries and concerns. Of course, the satisfaction provided by the doctor would be the main driver, and you need to develop your own soft skills and communication skills so that the patients feel reassured on meeting you, and you can inspire confidence in them. Learn to connect with your patients and empathize with their concerns. As you grow, try to provide more services like Retina etc. depending on the financial viability.

MANAGING THE TEAM MEMBERS

If you have other ophthalmologists and optometrists working for you, it is crucial and often difficult to keep them satisfied and motivated. One crucial factor is opportunities for financial and/ or professional growth. Also, be accessible to listen to genuine problems of your staff and give them a patient hearing. Just like your patients, the staff also wants to feel heard and understood. Do small activities, to foster the team spirit among all the members, and make them feel valued. At the same time, also let it be known that you observe everything, and any misdemeanors will be strictly acted upon.

ACHIEVING THE WORK-LIFE BALANCE

In a busy practice, efficiency is important to ensure that the patients are seen quickly, and your working time also doesn't overstretch. Learn to delegate all except the core work. Develop a good team and employ good quality staff that can take off some of your burden. Have enough staff to guide the patients and answer their queries and develop effective communication skills yourself, so that you can give a quick yet comprehensive explanation to the patient about his/ her condition. If your practice is managed efficiently, this will leave you time for your family. However, the most important factor for achieving a good work life balance is to firstly recognize its need and importance. Remember that your work is just one aspect of your life, which cannot replace the equally or often more important aspects like health and family. Ambition is an endless race, and therefore work to satisfy yourself and not get ahead of others.

HOW TO AVOID/MIMIMIZE LITIGATION?

While we are making tremendous progress on the global map, on the contrary, doctor–patient relationship is deteriorating, our internal medical setup is facing extensive problems with medical litigation being the most serious of all issues. The number of cases against eye care professionals for malpractice is increasing because of the increased awareness among the patients. While some cases may be legitimate and based on clinical negligence exercised by the doctors, most doctors are wrongfully accused because of the lack of public understanding. The eye care professionals must emphasize diligent service delivery and also maintain proper records about the patient history, consent, and treatment. ***ABC*** *to minimize medical errors during ophthalmic practice include:* ***A:*** *Accurate and complete documentation,* ***B:*** *Be clear and consistent, communicate effectively to explain pros and cons of treatment and establish good patient relationship,* ***C:*** *Consent, Checklists to avoid errors.* This practice will bring down the incidents of malpractice, and will protect the doctors from allegations and fake lawsuits.

TAKE HOME MESSAGE

For young ophthalmologists, we would say that running your own practice is a huge work and responsibility. Consider the option of 'Group Practice' and think well before you choose what exactly you want to do,. If you feel you are not cut out to handle all the responsibility (including clinical, financial, administrative etc.), choose another option like working in hospital or a shared facility. If you do choose to have your own practice, the initial few years are very crucial and remember to focus only on patient satisfaction at this time. Also, remember to be strong even if there are minor setbacks. Keep the big picture in mind, and do not fret over small things. In the end, remember that the ultimate aim of life is to be happy and professional success is just one means of achieving that along with many other things.

REFERENCES

1. Pandey Suresh. Secrets of Successful Doctors: A Complete Guide To A Fulfilling Medical Career. Maple Press, New Delhi, India 2019.

2. Pandey Suresh, Sharma Vidushi. A Hippocratic Odyssey: Lessons From A Doctor Couple On Life in Medicine, Challenges and Doctorprneurship . Bloomsbury, New Delhi, India 2020

3. Pandey Suresh. Entrepreneurship For Doctors: How To Build Your Own Successful Medical Practice? Maple Press, New Delhi, India 2021.

Restoring Dignity to Our Profession: Random Thoughts

Dr. Quresh B. Maskati

Consultant Eye Surgeon, Maskati Eye Clinic, Mumbai

E-mail: qureshmaskati@gmail.com

I thank the editor of ROS journal for inviting me to share my thoughts on a subject close to my heart. Let me start with a forward I received on What's App recently- Author Unknown.

Once upon a time there was a famous photographer who was invited by a prominent socialite to a very classy party. As he entered, the socialite greeted him effusively saying, "Mr. Rai, I have been an ardent admirer of your photographs for years! I am sure you must be having a superb camera". Mr. Rai said nothing. When it was time to leave, he profusely thanked the hostess saying, "Thank you Mrs. Sharma for an excellent and delicious meal – I am sure you must own an excellent stove!"

If you smiled or chuckled at this anecdote, please pause for a moment to reflect. How many times do we brag to our patients that we have the latest microscope or phaco-emulsification machine or that the IOL we are inserting is the 'world's best'. Are we not guilty of leading the patient to believe that the 'stove' is responsible for his or her excellent post-op vision rather than the 'cook'?

We, who are practicing eye surgeons, whether employed or in private practice labor long and hard to hone our skills. Unfortunately, many of us become 'cataractologists' along the way and extol the virtues of equipment we have to attract patients. There are twin dangers in doing this. First, we become slaves of the ophthalmic industry – we buy equipment we can ill afford and second, we are forced to use IOLs we may not wish to due to IOL bundling. Before we finish paying the loan amount on one machine or gadget, industry is already pressurizing us to upgrade "or you will be left behind as your neighboring eye surgeon has already upgraded"! We also make ourselves easy targets for Insurance companies and other payers to continuously reduce the amount payable for surgery as we tell patients that the surgery takes only 10 minutes and requires hardly any human touch due to the fancy 'robotic' or 'laser' equipment we own.

Young ophthalmologists, entering private practice and not having the means to afford all the hi-tech equipment and yet wishing to compete with seniors in the market place thus fall easy prey

for touts, pimps, family physicians offering 'cuts', taxi drivers promising to bring in patients, greedy newspapers and magazines promising print space in return for a hefty sum, FM channels giving advertising opportunities, etc. Seniors then bemoan the lack of ethics amongst the juniors.

Is there a way to restore the dignity of the profession? Can we survive in practice and still remain ethical? There is no easy answer and there is no magic solution. However, I offer the following suggestions:

1. Right from the time we first examine a potential patient in our clinics, we reassure him that we have the requisite skills to restore vision. If we have trained under a well-known guru or institution (as almost all young members of ROS have), we mention this to the patient. If we have passed out from a reputed university we display our certificate in the waiting room. We continuously reinforce the impression in the patient's mind that eye surgery is an art requiring years of training which we have. We inform him/her that of course we have all the equipment required to carry out the surgery effectively but do not put up giant posters of our phaco machine in our waiting rooms. We have learnt about up regulation and down regulation of cytokines in ocular inflammation, right? Similarly we should up regulate (or highlight our skill sets) and down regulate (or downplay) the role of the machines in restoring vision. That way, even if our neighboring eye surgeon gets a fancier machine it doesn't matter – our patients will come to us because of who WE are and not WHICH machines we have! We can upgrade our equipment whenever we feel the need to or only if we are convinced the new one will help us to further improve our results, not because the manufacturer is pushing us to buy!

2. What about quoting a package for the cataract surgery? In my clinic, there is a single package offered for unifocal IOL and one for multifocal/toric IOLs. I do my own counseling, but those that employ counselors should simply point out the pros and cons of unifocal versus premium IOLs and let the patient decide which type of IOL he wants. There is no way a patient can choose between 7 different packages for unifocal IOLs. When a person steps into a restaurant and chooses between French cuisine and say Italian pasta, he is making an informed choice based on knowledge of what each food item tastes like, not merely its price. However, when you create 7 packages in Unifocal IOLs with different prices for an Alcon or Zeiss or Rayner or a cheaper foldable IOL, the patient is confused and neither you nor the most experienced counselor can explain to the patient's satisfaction what the difference is between the packages except for the cost! Even after the patient chooses a particular IOL based purely on price, he wonders if he should have sold his wife's jewellery and opted for the highest package! Every time he gets a little redness or irritation post op he regrets that he did not go for a higher package!

   Why not simply tell him there is a single package costing XXXX. If he says he cannot afford it, or you or your counselor feels he cannot afford it, give him a discount of

whatever percentage you feel comfortable. You can then choose to implant a cheaper IOL if you wish, depending on the final price you have agreed on for the package. You still reassure the patient that he will get an excellent IOL and an excellent result irrespective of his paying less. The patient is not interested in knowing the brand of IOL (in a majority of cases) – he only wants to hear from your mouth that everything will be all right. In more than 90% of my cases, the patient learns what IOL has been inserted only after the surgery when the IOL sticker and box etc. are given to him/her. A small number of patients come to me telling me they want only a particular brand put in as they have perhaps read the advertisement somewhere (in some other doctor's cabin) or a friend or relative has had this IOL and is seeing well. For this minority I will inform that all IOLs are good and I will put the IOL of his brand choice (no discount!).

3. My advice to youngsters starting practice is to do a group practice. Get together with batch mates or like- minded colleagues and reduce your individual investment both in the OPD and in the surgical equipment. Do sign a proper contract amongst yourselves with an entry and exit clause to avoid needless acrimony if one of the partners wishes to leave or start their own set-up. In unity there is a lot of strength. Your income will still continue if you take a holiday or are unwell for some time. You will find it a lot easier to upgrade your equipment from time to time and can expand as you grow, either by taking in new partners or opening more centers.

4. My advice to senior colleagues who already have their own set-ups – either day care centers or small or medium sized eye hospitals, is to invite junior colleagues starting practice to operate in your premises. You can charge them a fee of course, but since it will be on a per case basis, it will be hugely more affordable for a youngster than to purchase his own space and equip a modern sterile OT and hire the staff necessary when he does not have enough surgical work to sustain the tremendous investment in his early years. It is a win-win situation for both: the senior optimizes use of his OR, which would have remained idle when he was not using it and gets the satisfaction of mentoring a junior who will in all probability refer his complicated cases to him as they are on the same premises. The junior of course gets an excellent OR and does not have to bother about managing fumigation etc. If adequate space exists, it would be ideal for the junior to bring in his own microscope and phaco machine and small instruments so that he is responsible for maintenance of his own equipment and there are no accusations flying around if a probe breaks down or a microscope malfunctions.

5. If you are practicing in a small town having 10 or less ophthalmologists, it is imperative that you get along with each other. If there is back biting amongst yourselves, you will all lose in the long run and patients will often migrate to another town or city for surgery. One way to foster harmony is to have dinners at regular intervals – these can be self -

sponsored or you could rope in a pharma company to have a CME. Let the whole thing be informal. Have a co-coordinator amongst yourselves if you wish, whose role is merely to fix one or 2 CME topics and decide which of you is going to make a small presentation. It could be once in 2-3 months. The moment you have an association with president, secretary etc. there could be ego clashes. For every meeting you could have a different co-coordinator. This will sponsor collegiality and a healthy relationship between all.

I will end with a story. If you take a 2000 Rupee note and fold it till it becomes a fraction of its size, or rub it in the mud or pour cold water over it or run a steam roller over it and then take it to the store, the shopkeeper will still give you 2000 rupees worth of groceries. Similarly let no one – whether it is a nasty patient or a colleague or sometimes a senior, reduce your self-esteem. Each of us is unique, like a diamond. We should be aware of our true worth always. Remain dignified, remain ethical and convince patients that we are fully capable of helping them see better with the resources we have, because it is our skill that matters, and nothing else!

Teaching and Training Residents During the COVID-19 Era: Challenges and Possible Solutions

Dr. Suresh K. Pandey, Dr. Vidushi Sharma

SuVi Eye Institute & Lasik Laser Center

C 13 Talwandi, Kota, Rajasthan

E-mail: suvieye@gmail.com

The outbreak of Coronavirus Disease-2019 (COVID-19) has impacted different aspects of life for people all around the world. Residents at different levels of education are among those who have been significantly affected by this pandemic. As a higher level of education, ophthalmology residency is a top specialty in different parts of the world including India.

INADEQUATE TRAINING IN DURING THE COVID-19 ERA

On 11th March 2020, the World Health Organization (WHO) declared the COVID-19 caused by the 2019 novel coronavirus (2019-nCoV) a pandemic. This has brought radical changes in all aspects of our lives and hampered the training. Social distancing and restrictive movement policies have markedly deranged traditional educational practices. The time course of these changes is indeterminate. These have affected conventional in-person ophthalmic education and training. There is a pressing need to innovate and implement alternative educational and assessment strategies. *The COVID-19 pandemic has provided us with an opportunity to pave the way for introducing digital learning in ophthalmology. The virtual classrooms can be conducted using platforms such as video conferencing (Google Hangouts Meet, Zoom, Slack, CiscoWebEx) and customizable cloud-based learning management platforms (Elias, Moodle). The digital learning carry a lot of advantages however it cannot be replaced by "hands-on training".*

NEED FOR STANDARDIZATION OF RESIDENCY TRAINING IN INDIA

Sadly, surgical training of ophthalmology residents in India and several developing countries in most of the residency programs has not kept pace with these advances. Cataract surgery is most commonly performed surgical procedures. Most of the medical colleges in India and developing world still focus exclusively on Small Incision Cataract Surgery (SICS), and even traditional Extra-Capsular Cataract Extraction (ECCE) during the ophthalmology residency. These techniques certainly have an important role for selected patients in developing countries. However, we must make sure that our ophthalmology residents are equally well versed with micro-incision cataract surgery-phacoemulsification and other newer developments (including premium IOLs) which are now considered the standard of care for cataract patients, with few

exceptions. The need for better curriculum and uniformly applied, well-structured goals for surgical training during residency training cannot be overemphasized.[1-8]

As someone who received training in ophthalmology from a regular medical college in India followed by one of India's premier institutions (PGIMER, Chandigarh/AIIMS, New Delhi) and finally at a world class teaching eye hospital (Storm Eye Institute, Charleston & John A Moran Eye Center, Salt Lake City, Utah, USA), we can affirm that surgical training standards in India and other developing countries are hugely capricious, and need to be standardized. We have emphasized the challenges faced by ophthalmology trainees and possible solution for transferring surgical skills in young ophthalmologists in a recently published editorial.[9]

While some well-funded and eminently staffed institutions in the government (e.g. Dr. R P Center for Ophthalmic Sciences, AIIMS, New Delhi, PGIMER, Chandigarh, India) and non-government sector (L. V. Prasad Eye Institute, Hyderabad, and Aravind Eye Care System, Madurai) in India have excellent surgical training programs, the vast majority of medical colleges offer little to no "hands on" training in ophthalmic micro-surgery (including micro-incision cataract surgery). This revealing fact was unambiguously presented in a landmark study on general residency training standards in India, published in this journal in 2008.4 Another study published in 2017 found that cataract surgical training during residency focused only on SICS.[5]

Apart from a couple of institutions, ophthalmology residents in India and the developing world do not have access to virtual reality training systems. 'Hands-on' training is practically the only system of transferring surgical skills in India and developing countries. While residents do get to learn "hands-on" surgery, in addition to high patient expectation about quick visual recovery (after cataract-IOL surgery), there are various procedural and administrative issues that hamper learning.

CHALLENGES FACED DURING SURGICAL TRAINING AND HOW TO OVERCOME THEM?

In many teaching institutions in India and the developing world, the hierarchal system of case allocation followed is usually such that residents/trainee get the cases at the end of the operating theatre list or at a side table, where surgical instruments, operating microscopes, machines, assistants, support staff and often patient preparation, are all sub-optimal. Most of the times, these resident surgeries are either unsupervised, or supervision is carried out by other, more senior residents, who themselves are in the learning phase. There is a need to change these processes so that ophthalmology residents have a better atmosphere to learn.

POSSIBLE SOLUTION FOR IMPROVING TRAINING

Several authors have suggested an urgent need to improve ophthalmology residency training in medical colleges of India.[3-5] This necessitates strong will power (for teachers) to teach the residents, industry support to provide equipments at discounted price, funds to buy new equipment(s), and to maintain them, "training the trainers", standardized and monitored residency curriculum etc., but most importantly -the desire and the drive to make resident training the focus of all activities in training institutes. The residents themselves need to become

proactive to achieve the best possible training, utilizing the host of resources (including articles, surgical videos available on internet) that have become available in recent times.

BENEFITS OF PRACTICING OCULAR MICRO-SURGERY IN WET LAB

Wet Labs/surgical simulators can be a very helpful option for learning various steps of phacoemulsification before proceeding for "hands-on" micro incision cataract surgery & IOL implantation. Wet lab training allows residents to get familiar with phacodynamics/phaco machine settings, operating microscope, ophthalmic microsurgical instruments and definitely helps to minimize the learning curve. Animal eyes, postmortem human eyes (Miyake-Apple preparation), simulators, devices, teaching tools such as Kitaro dry lab and wet lab system kit (FCI Ophthalmics, Pembroke, MA, USA) are currently available to learn and practice phacoemulsification surgery in a stress-free environment (Figure 1).[10-12] All India Ophthalmological Society and state ophthalmological societies and several other not-for-profit organizations are doing an excellent job with skills transfer courses where many ophthalmology residents and fellows get exposure to an interaction with experts in the field.

Figure 1: *Kitaro Cataract Drylab & Kitaro Cataract Wetlab (Courtesy: FCI Ophthalmics Inc., USA)*

HOW TO OVERCOME CHALLENGES OF LEARNING EYE SURGERIES/PHACO?

Common pitfalls while learning phacoemulsification (poor incision construction, inability to achieve complete capsulorhexis, inadequate hydrodissection, inability to crack the nucleus, iatrogenic zonular dialysis, posterior capsule rent, vitreous loss, nucleus drop, difficulty to load and implant IOL in the capsular bag etc.) can be avoided using new blades for creating incision, good quality OVD, and compulsory wet lab training to minimize learning curve related mishaps. Practice of suturing with 10-0 monofilament nylon under surgical microscope helps residents be ready when they encounter leaky incisions. Encouraging ambidexterity in residents can help improve surgical skills, too. A focus on supervised ophthalmic surgery needs to be created, with senior experienced faculty performing the skill transfer duty, rather than novice surgeons.

TIPS TO MINIMIZE COMPLICATIONS?

We need to remember that the best of surgeons have made mistakes while learning. However, since we are dealing with human eyes, we can neither afford to make too many mistakes nor

leave mistakes unattended. Whenever a mistake is made, an effort should be made to find the cause, learn to avoid it and rectify the same. Surgical video recording and review of videos by self and teachers, especially in case of complication can go a long way in imparting surgical skills while at the same time improving the quality of surgery. As teachers, we also need to inculcate the sense of responsibility in residents to see and care for the operated patient in the postoperative period- where they can learn the nuances of postoperative care.

ROLE OF PRIVATE SECTOR

The private sector forms a large part of Indian healthcare scenario and most private practitioners (ophthalmologists) are actively involved in academic activities. Engaging them in surgical training of residents can refine the latter's learning to make them ready for real- life practice scenarios. Out of the box solutions can be adopted where necessary e.g. better collaboration between medical colleges and institutes in the private sector or allowing honorary teaching in colleges by private practitioners.

PEARLS FOR WOMEN RESIDENTS IN OPHTHALMOLOGY

Ophthalmology is becoming a preferred branch for female doctors as career as an eye specialist is considered rewarding for women wanting to maintain a work life and work family balance. It is extremely important for all resident doctors to get the best possible training during their residency. This is even more pertinent for women residents, as it becomes very difficult to devote time to full time rigorous training programs at a later stage in life, particularly after marriage and kids. At an early age, it is possible to travel far and wide for the best training opportunities, especially in surgical disciplines like ophthalmology. Current ophthalmology practice is becoming difficult because of heightened patient expectations and an aggressive consumer culture that is spreading fast. In such a scenario, it is absolutely essential to get the best possible clinical training, so that their competence can become their big strength when these residents start doing clinical practice.

ROLE OF MENTORS

For mentors and teachers, teaching can indeed be challenging in a changing era of mentor protégé relationship. The residents of ophthalmology now are more focused and competitive than ever before. Some of them may suffer from work related stress due to excessive work load while others may have attitude problem, may not be doing their duties properly and lacking the basic discipline and a mindset that lacks respect for their seniors and mentors. Also, their learning style, as well as exposure to innovative learning modes has increased their expectations from their mentors and teachers. On the other hand, the mentors and teachers feel these young ophthalmologists just want to learn things way too quickly and on their own. There is a dire need to find a middle ground and for that there is a major need to create mutual goals that must be implemented. It is important to utilize the innovative teaching styles and techniques to help these technically driven residents to learn more efficiently. It is essential to keep in mind that these young ophthalmologists are the future of ophthalmology. Steps need to be taken to make

immediate changes in the training and teaching in ophthalmology residency to ensure a bright and prosperous future of ophthalmology in India.

LEADERSHIP MANTRAS FOR RESIDENTS/YOUNG OPHTHAMOLOGISTS?

There are numerous ways through which the resident/young ophthalmologists can become leaders of tomorrow. Firstly, it is essential for them to find the right mentor, someone who is genuinely interested in helping them adapt leadership qualities instead of someone who hardly offers any useful advice. Most importantly, they have to actually listen to their mentors, even if it is a hard feedback. Moreover, young ophthalmologists need to become more proactive if they truly want to become future leaders. [13-16] There is no point in waiting for someone to hand them the responsibilities, they need to show their mentors and leaders that they have what it takes to be in a leadership role. These future leaders should also be engaged in member organizations right from the initial stage. Another important thing these young ophthalmologists must consider is stepping out of their comfort zone. They must trust their education and training, and must not be afraid to learn new technique and skill that can open more opportunities for them to move on to leadership roles. [15]

TAKE HOME MESSAGE

It is important to perform and validate residency examination and evaluations in a standardized and uniform electronic format. Attention should also be paid to necessary changes in the national curriculum of ophthalmology residency education, to prepare residents with non-surgical but fundamental skills such as crisis management and teamwork. Additionally, as a priority, we must ensure that our trainees are and will be safe and healthy during their education period, therefore all necessary protective equipment and measures should be provided to fulfill this goal.

Virtual education in the ophthalmic field is here to stay even after the pandemic. Ophthalmology as a branch has always been using cutting edge technology for clinical and surgical care; it's time now to use it for proving maximum clinical, hands-on training and education of our residents. We need to use COVID-19 opportunity to grow as teachers and as professionals. It is important to make the best of the situation and maintain a positive attitude. Let us inspire all young ophthalmologists as mentioned by *William Arthur Ward- The great teacher inspires, The good teacher explains, The superior teacher demonstrates, The mediocre teacher tells.*

REFERENCES

1. Baxter JM, Lee R, Sharp JAH, Foss AJE, Intensive Cataract Training Study Group. Intensive cataract training: a novel approach. Eye (Lond) 2013; 27: 742–746.
2. Ajay K, Krishnaprasad R, Divya DS. Ophthalmic surgical training in Karnataka and Southern India: Present status and future interests from a survey of final-year residents. Indian J Ophthalmol 2015; 63:306-311
3. Khan MD, Quresh MB. Training a Cataract Surgeon. Community Eye Health. 2002; 15: 21–22.

4. Thomas R, Dogra M. An evaluation of medical college departments of ophthalmology in India and change following provision of modern instrumentation and training. Indian J Ophthalmol 2008; 56:9-16.
5. Ajay K, Krishnaprasad R, Divya DS. Ophthalmic surgical training in Karnataka and Southern India: Present status and future interests from a survey of final-year residents. Indian J Ophthalmol 2015; 63:306-11.
6. Grover AK. Postgraduate ophthalmic education in India: Are we on the right track? Indian J Ophthalmol 2008; 56:3–4.
7. Gogate P, Biswas P, Natarajan S, Ramamurthy D, Bhattacharya D, Golnik K, et al. Residency evaluation and adherence design study: Young ophthalmologists' perception of their residency programs – Clinical and surgical skills. Indian J Ophthalmol 2017; 65:452–60.
8. Gupta A. Ophthalmology postgraduate training in India: Stirring up a hornet's nest. Indian J Ophthalmol 2017; 65:433-4.
9. Pandey SK, Sharma V. Cataract surgery training during ophthalmology residency in India: Challenges and how to overcome them? Indian J Ophthalmol 2017; 65:1279-80
10. Pandey SK, Werner L, Escobar-Gomez M, Roig-Melo EA, Apple DJ. Dye-enhanced cataract surgery. Part 1: anterior capsule staining for capsulorhexis in advanced/white cataract. J Cataract Refract Surg 2000; 26:1052-9.
11. Pandey SK, Werner L, Vasavada AR, Apple DJ. Induction of cataracts of varying degrees of hardness in human eyes obtained postmortem for cataract surgeon training. Am J Ophthalmol 2000; 129:557-8.
12. Pandey SK, Werner L, Escobar-Gomez M, Visessook N, Peng Q, Apple DJ. Creating Cataracts of Varying Hardness to Practice Extracapsular Cataract Extraction and Phacoemulsification. J Cataract Refract Surg 2000; 26, 322-9.
13. Grover AK., Honavar SG., Azad R., Verma L. A national curriculum for ophthalmology residency training. Indian J Ophthalmol, 2018; 66 (6): 752-83.
14. Foist, C. 6 Tips for Young Ophthalmologists from 2018 President Keith Carter, MD. American Academy of Ophthalmology 2018; Retrieved from https://www.aao.org/young-ophthalmologists/yo-info/article/6-tips-for-yos-from-2018-academy-president
15. Mets, MB., Brown A., Doan, AP., et al. The Ophthalmologist of the Future. Arch Ophthalmol 2012; 130 (9): 1190 -1194.
16. Pandey SK, Sharma V. Ophthalmology training and teaching in India: How these young ophthalmologists can become leaders of tomorrow?. Indian J Ophthalmol2018;66:1517-8

Image on the Cover Page

Contributed by
Dr Abhishek Kothari,
MS, FRCS, FICO, FMRF
Consultant Vitreoretinal Surgeon,
Pink City, Eye and Retina Center, Jaipur
E-mail : dr.a.kothari@gmail.com

Tuberculosis is still prevalent in India, and Ocular Tuberculosis can have myriad presentations. The cover picture depicts a large macular subretinal cyst- the intraocular version of 'cold abscess'. It is rare to encounter this type of lesion – intraocular tuberculosis with a large subretinal abscess, but without noticeable inflammation. The most common form of tubercular involvement of the eye presents as chronic uveitis, or miliary choroidal tubercles. In this patient's case, no evidence of tuberculosis was found on HRCT Chest and CT of the brain. In the absence of any indirect evidence, the diagnosis and successful treatment rested totally on invasive vitreous biopsy and a unique PCR-based test of the sample. With accurate diagnosis and treatment, the patient demonstrated excellent recovery with resolution of the lesion and restoration of vision to 6/6, N6. *Awareness of latest available diagnostic tests and their capabilities helps reach the diagnosis and avert unnecessary morbidity in these rare cases.*

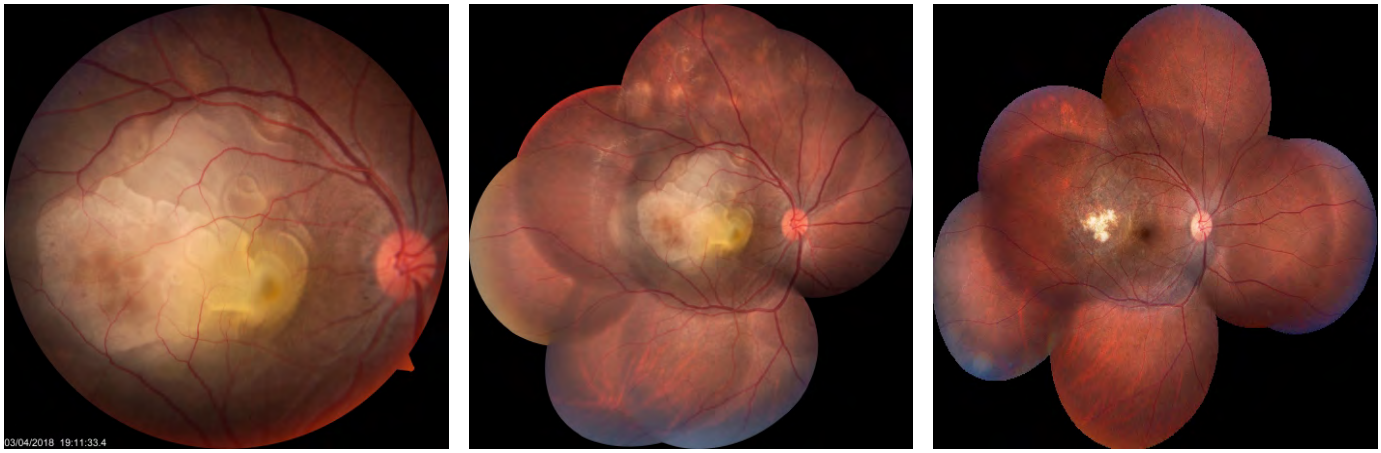

Ophthalmic "PEN"nings

Dr. Sunil Gupta, MS
Consultant Glaucoma Surgeon
Ram Avtar Eye Hospital & Glaucoma Pavilion, Jaipur

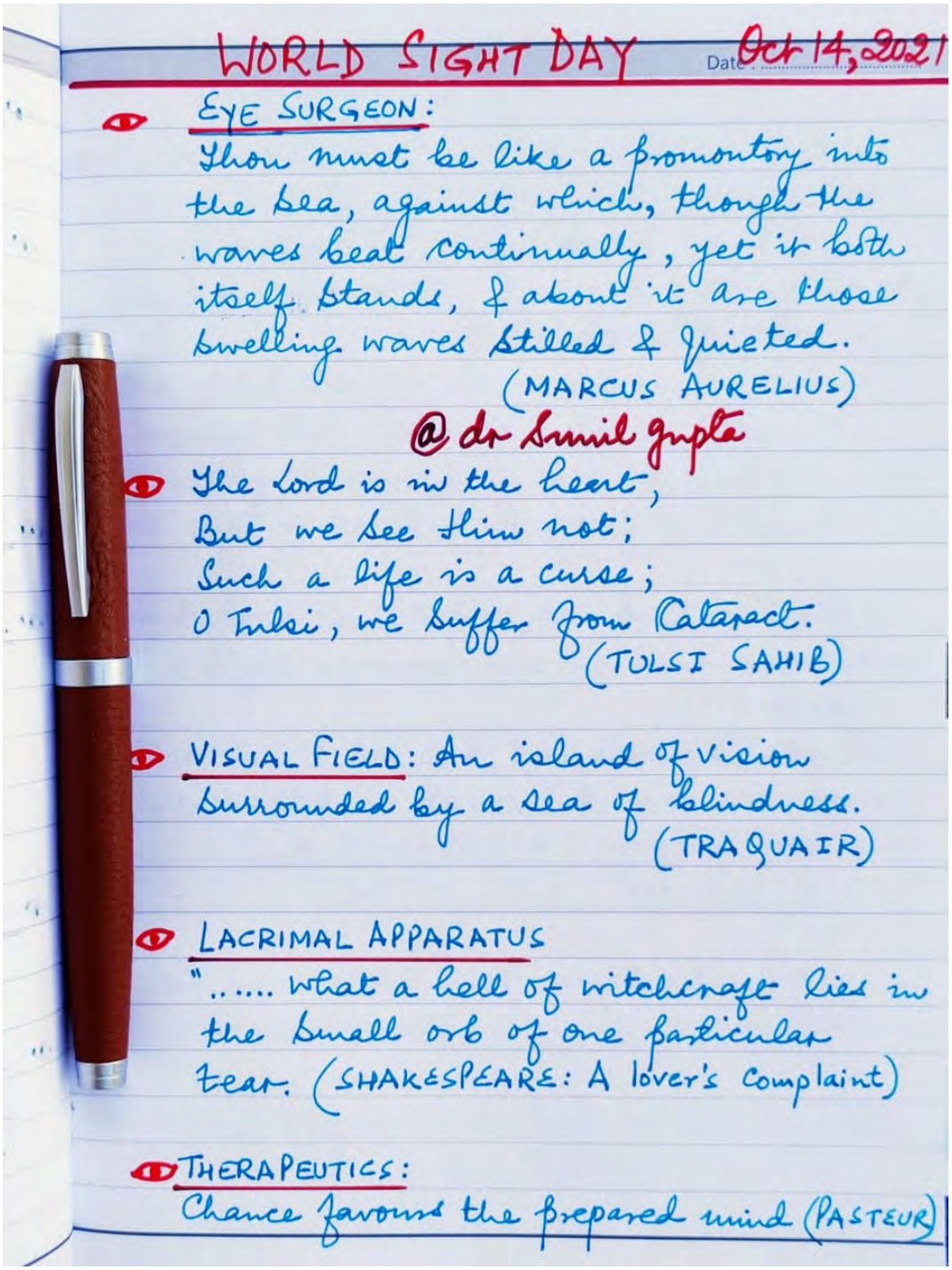

WORLD SIGHT DAY Date: Oct 14, 2021

EYE SURGEON:
Thou must be like a promontory into the sea, against which, though the waves beat continually, yet it both itself stands, & about it are those swelling waves stilled & quieted.
(MARCUS AURELIUS)

@ dr Sunil gupta

The Lord is in the heart,
But we see him not;
Such a life is a curse;
O Tulsi, we suffer from Cataract.
(TULSI SAHIB)

VISUAL FIELD: An island of vision surrounded by a sea of blindness.
(TRAQUAIR)

LACRIMAL APPARATUS
"..... what a hell of witchcraft lies in the small orb of one particular tear. (SHAKESPEARE: A lover's Complaint)

THERAPEUTICS:
Chance favours the prepared mind (PASTEUR)

NOTES

Raymed

100% Vegan | 30 GUMMIES

Vitamax®

G-U-M-M-I-E-S

Lutein 4 mg, Astaxanthin 1600 mcg,
Zeaxanthin 800 mcg, Vitamin A 499.8 mcg,
Vitamin C 30 mg, Vitamin E 5.04 mg, Docosahexaenoic acid (DHA) 100 mg

PROTECTION FROM DIGITAL LIGHT-GREAT EYESIGHT

Protect your eyes with the NEW AGE SUPPLEMENT

A Complete Nutritional Supplement

- Helps reduce eye strain & fatigue
- Protects from blue light damage
- Supports long term eye & vision health

GUMMIES *A new dosage form* | Deliciously healthy | Convenient dosage form | Tempting taste, color and appearance

Raymed

Raymed Pharmaceuticals Limited
Corporate Office: SCO-859, Manimajra, Chandigarh
E-mail : admin@raymedindia.com, Website : www.raymedindia.com

care GROUP
LOOK FORWARD

SINCE 1987

Magnificent UHD

Ultra High Depth of Focus

- **Abberation** Controlled
- **Blue Blocker** Yellow
- **Enhanced** Contrast
- **Square** Edge

Precise Cast Molded Hydrophobic MICL

iCL v2.0 IMPLANTABLE PHAKIC Contact Lens

One Step **Refractive Solution** for
Myopia, Hyperopia and Presbyopia with Astigmatism Correction

Good-bye To Daily Inconvenience Of Glasses

- **Central** Hole
- **Proprietary** Material
- **No** Visual Disturbances

Implanted worldwide in more than 20 countries

Spectacles Free Vision for All

TRiPhobic HD

True Trifocal Hydrophobic MICL

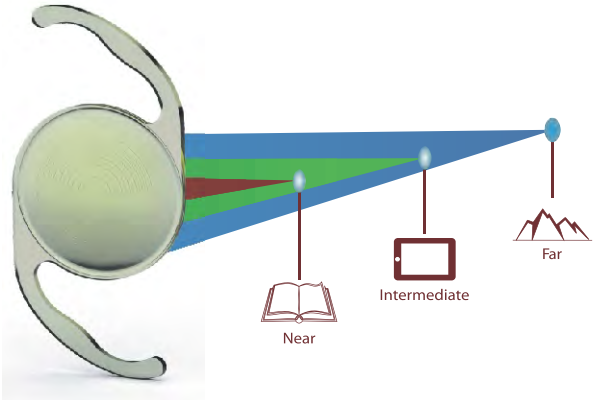

Dynamic Energy Transfer Optic

- **Refractive-Diffractive** Optic
- **Slanted** Transition Zones
- **360°** Square Edge
- **Aberration** Neutral

For Near, Intermediate and Distant Vision

www.caregroupiol.com

The 1st Progressive EDOF IOL

Everything in Focus

well mini

well mini PROXA

Well Fusion Optical System

The Begining of New Era

Zydus Occuvia | SIFI